脑血管肌纤维发育不良

脑血管肌纤维发育不良

（Fibromuscular Dysplasis）

刘昊

南昌大学第二附属医院神经内科

脑血管肌纤维发育不良

- 1938年Leadbetter及Burkland首次报道一例肾动脉受累的FMD患者（当时称为纤维肌性成分增生）
- 1960年后改称为肌纤维发育不良(FMD)。
- 1964年Palubinskas和Ripley首次报道头颈部受累的患者。
- 1991年国内开始报道。

脑血管肌纤维发育不良

肌纤维发育不良（FMD）

- 特发性全身血管病
- 中小动脉
- 非动脉硬化性平滑肌和弹性组织异常。
- 多部位，最常见于肾动脉、颈内动脉，部分累及内脏动脉
- 常为双侧对称性病灶。

脑血管肌纤维发育不良

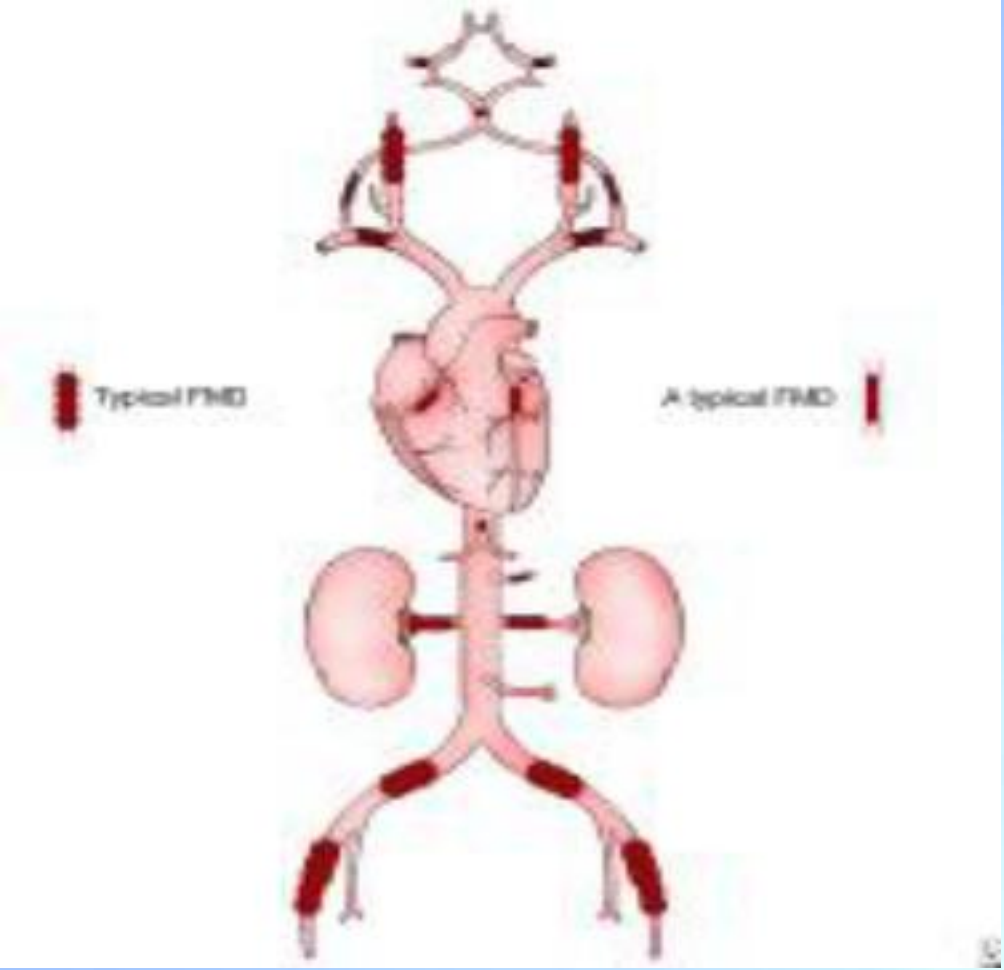

FMD主要累及全身中等大小的动脉

脑血管肌纤维发育不良

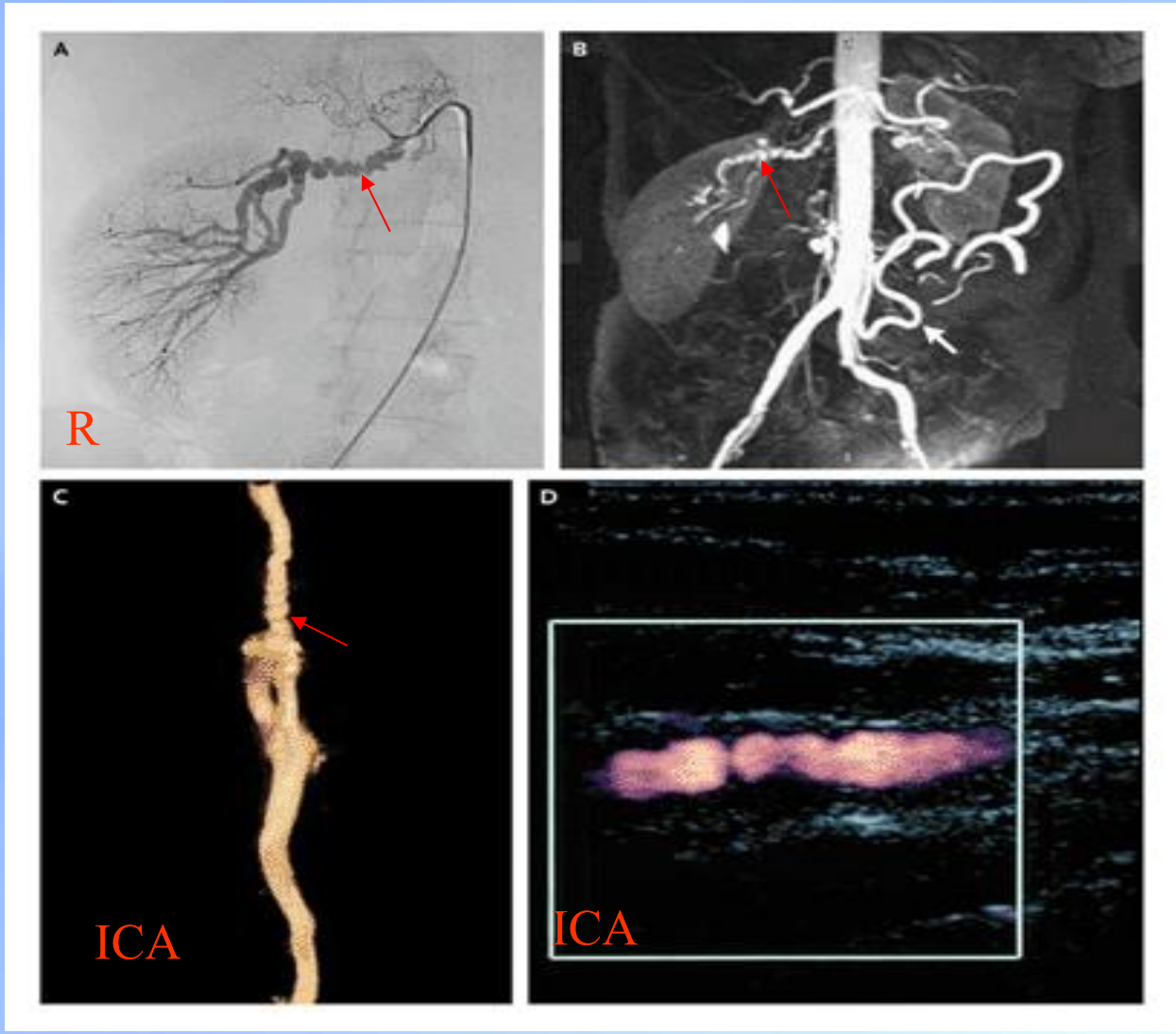

A 55-year-old woman presented with hypertension that was difficult to control

流行病学

- 30～50岁的女性多见
- 男：女为1：3－4
- 婴儿罕见。
- 部分患者有家族遗传性。

流行病学

脑血管肌纤维发育不良

- 肾动脉受累60％－75％
- 脑动脉受累25％－30％(85％是中年女性)

  95％颈内动脉受累

  12－43％椎动脉受累

  颅内动脉受累少见
- 内脏血管受累约9％
- 肢体血管受累约5％

- 26％患者有一处以上动脉节段受累

病因

- 病因不明
- 血管壁的血管缺陷、反复的损伤、内分泌障碍或a一抗胰蛋白酶缺乏有关。
- 在先天性遗传缺陷基础上，加之吸烟、高血压、激素、血管壁缺血、代谢、免疫异常等因素所致。

病理

脑血管肌纤维发育不良

- 平滑肌增生或变薄
- 弹性纤维破坏
- 纤维组织增生
- 动脉壁紊乱
- 没有炎症、坏死、脂质聚集及钙化或动脉粥样硬化的病理表现
- 合并动脉瘤及动脉夹层

病理分型

1. 内膜纤维组织形成
2. 中膜纤维组织形成
   - 2.1 中膜发育不良
   - 2.2 中膜外纤维组织形成
   - 2.3 中膜过度增生
3. 外膜纤维组织形成

病理分型

脑血管肌纤维发育不良

1. 内膜纤维组织形成：

- 占FMD的10％
- 胶原在血管内膜沉积
- 内弹力板分裂
- 血管腔呈较短的向心性狭窄
- 血管造影表现为环状狭窄

病理分型

脑血管肌纤维发育不良

2. 中膜纤维组织形成

2.1 中膜发育不良

- 占FMD的80％
- 中膜增厚和变薄区域交替出现
- 增厚区纤维增生、胶原沉积
- 血管造影表现为典型的串珠样改变

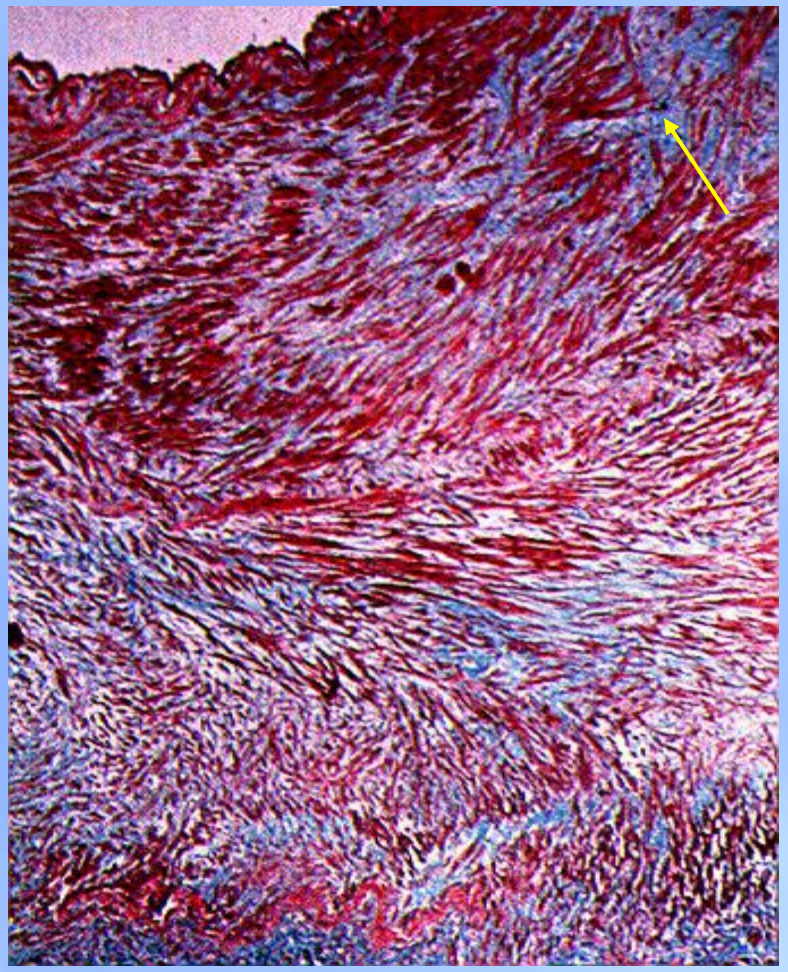

A cause of renal artery stenosis, In this trichrome stain there is excess collagen (blue) throughout the thickened media.

medial fibroplasia

病理分型

脑血管肌纤维发育不良

2. 中膜纤维组织形成

2.2 中膜外纤维组织形成

- 占FMD的10－15％
- 斑片样胶原沉积
- 外弹力板不分裂
- 血管造影可以表现为串珠样改变，但并无管径扩张

病理分型

2. 中膜纤维组织形成

2.3 中膜过度增生：

- 占FMD的1－2％
- 平滑肌向心性增生，无纤维化

病理分型

3. 外膜纤维组织形成

- 占FMD的1%
- 外膜中疏松的结缔组织被致密的纤维组织所替代

病理

- 各种类型FMD形态发生过程是相同的
- 亚细胞水平的病变是相似的，只是密度和位置不同
- 最核心的变化是平滑肌细胞发生成纤维细胞样转化

影像学

血管造影：

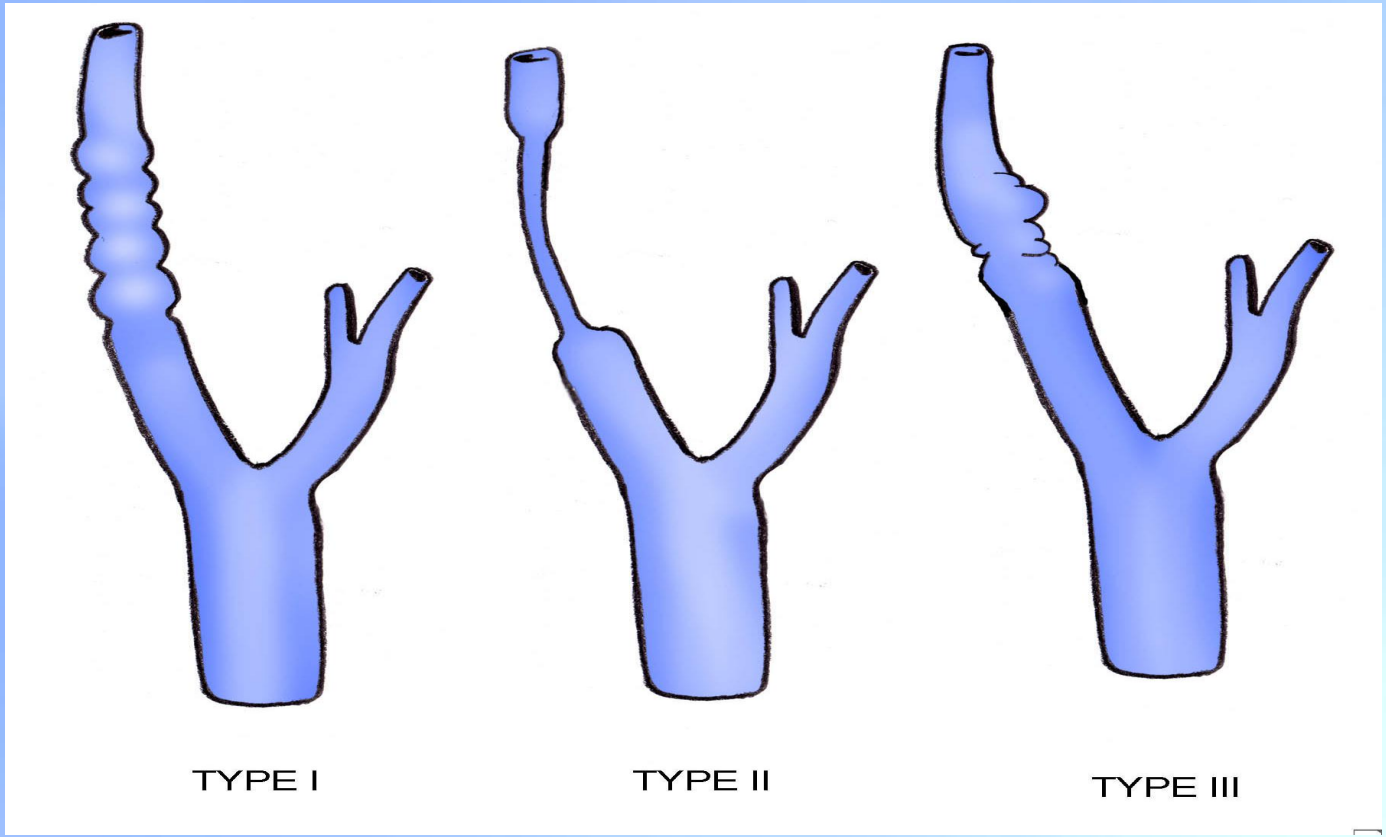

串珠状	平滑管状	憩室型
80%－85%	6%－12%	4%－6%

脑血管肌纤维发育不良

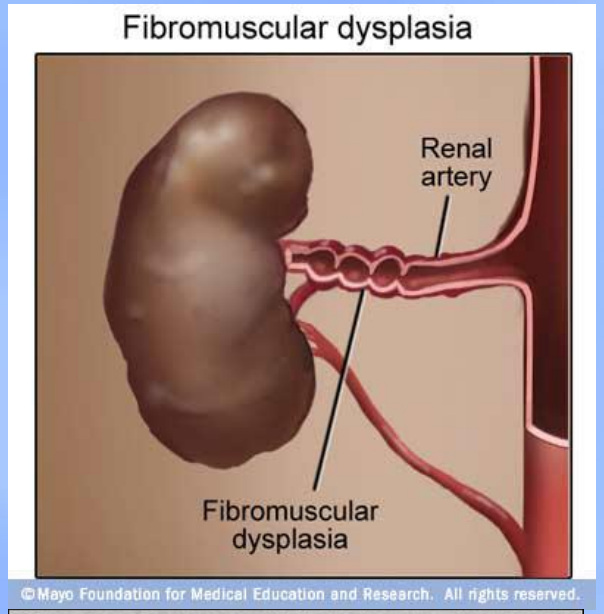
Fibromuscular dysplasia
Renal artery
Fibromuscular dysplasia
©Mayo Foundation for Medical Education and Research. All rights reserved.

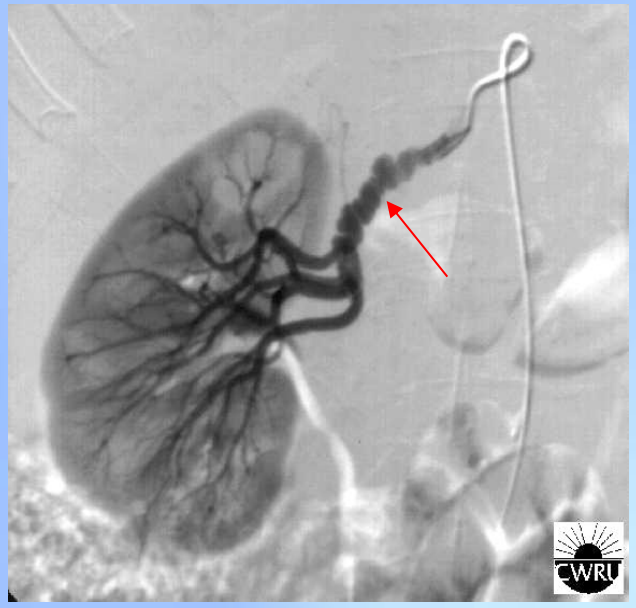
CWRU

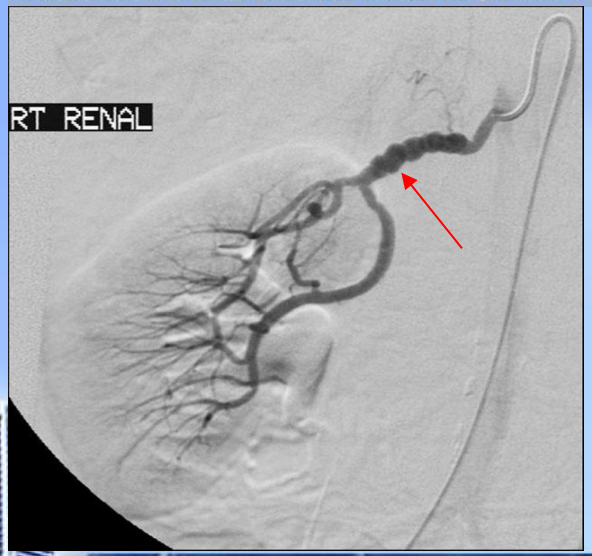
RT RENAL

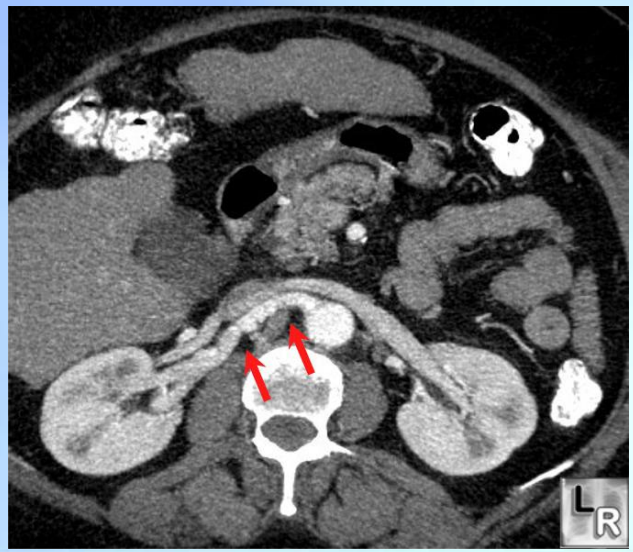
L
R

脑血管肌纤维发育不良

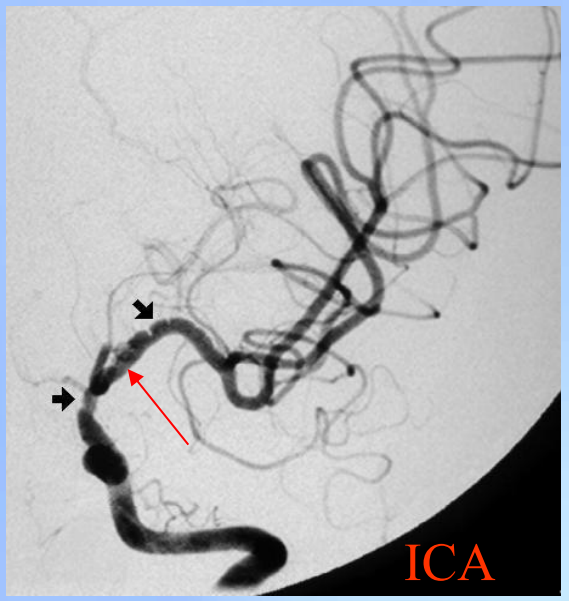

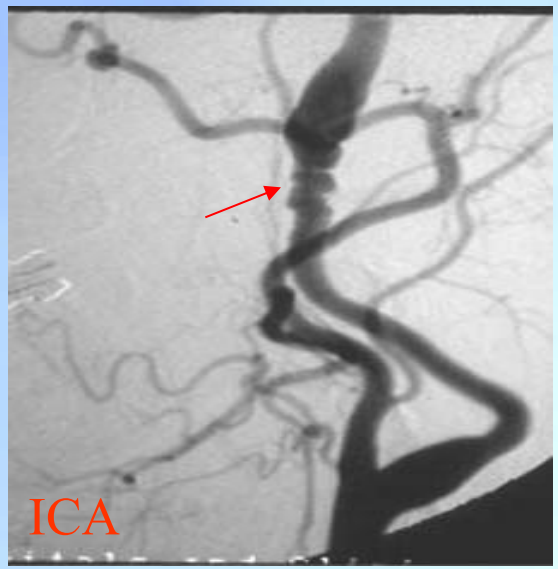

a 52-year-old woman sufferning from recurrent transient ischemic attacks.

脑血管肌纤维发育不良

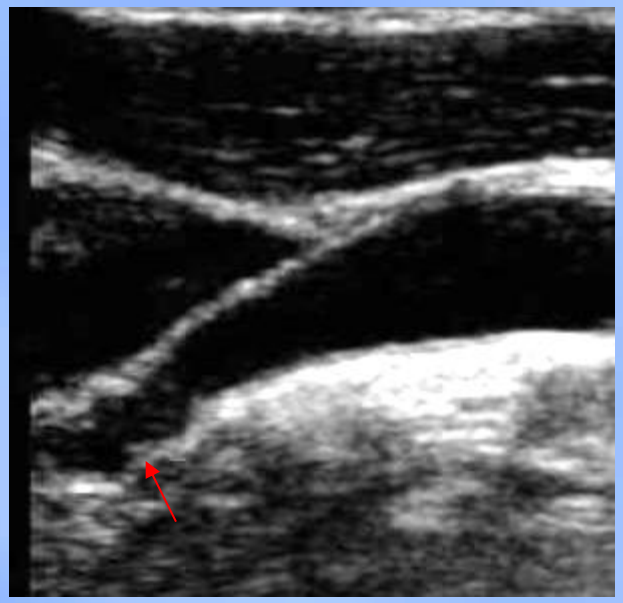

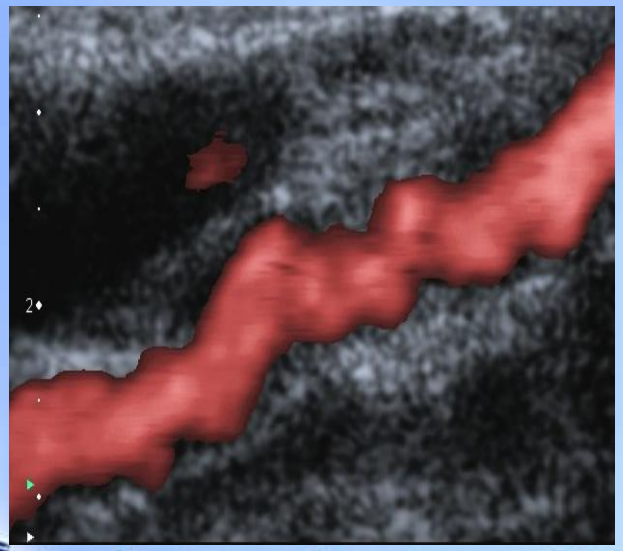

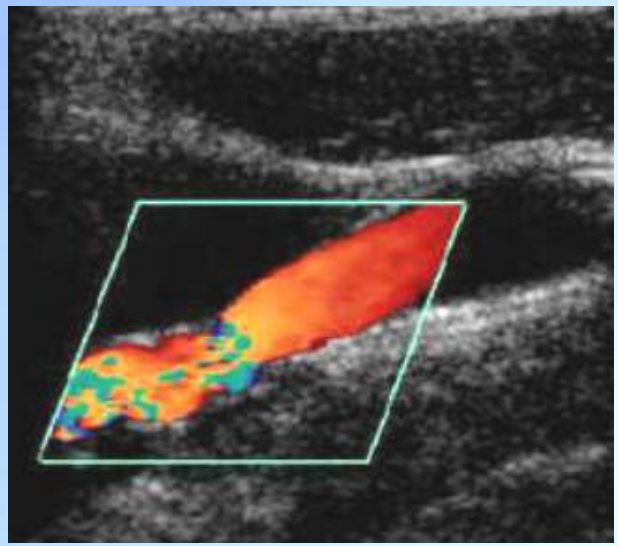

脑血管肌纤维发育不良

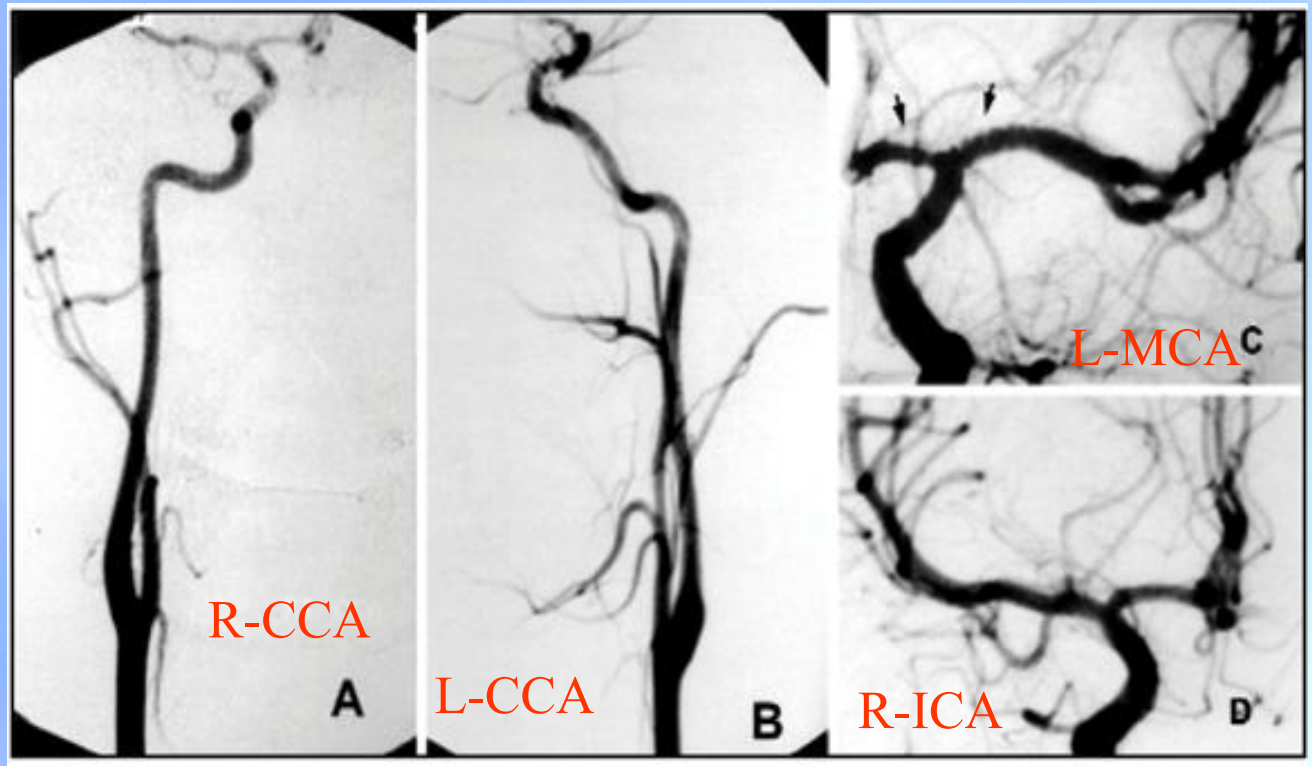

Fig 2. Digital subtraction angiography of the right (A) and left (B) common carotid arteries revealed normal vessels. Left internal carotid artery injection, in frontal view, clearly demonstrated luminal irregularities (arrows) in the proximal left anterior and middle cerebral arteries (C). Angiogram of the right internal carotid circulation, in frontal projection, showed normal vessels (D).

脑血管肌纤维发育不良

影像学

颈动脉病变的FMD患者

- 约95％的病变位于受累动脉的中1/3段
- 最常位于颈椎第1、2椎体水平
- 颈内动脉近端不受累。

脑血管肌纤维发育不良

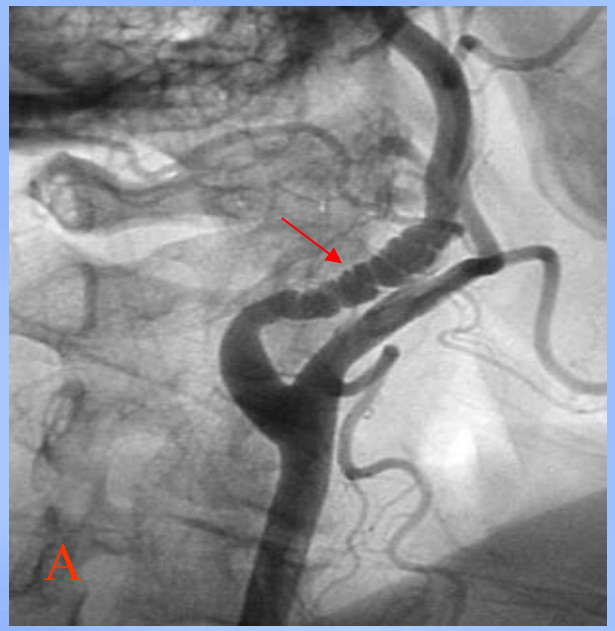

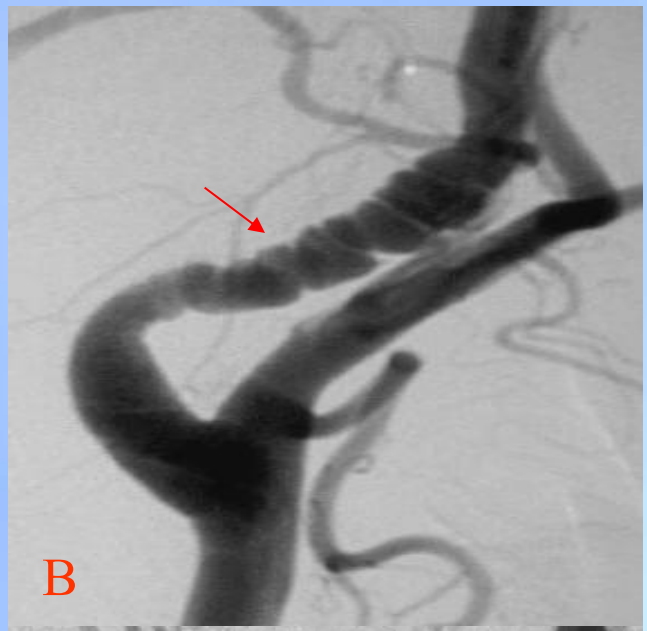

a 43-year-old female patient with multiple transient ischemic attacks. Note the multiple saccular dilatations of the internal carotid artery between the first and second cervical vertebrae（A）. Anterior communicating artery aneurysm. An increased association of aneurysm formation is seen in patients with fibromuscular dysplasia(C).

脑血管肌纤维发育不良

临床表现

1. 头颈部动脉FMD
2. 颈动脉颅外段FMD
3. 椎动脉颅外段FMD
4. 颅内动脉FMD

脑血管肌纤维发育不良

鉴别诊断

	FMD	AS
年龄	30－50	中老年
性别	女性多见	男性多见
脑血管危险因素	多无	多合并
病变部位	血管1/2－远端1/3	血管近端
与正常血管分界	清楚	不清楚

脑血管肌纤维发育不良

鉴别诊断

FMD

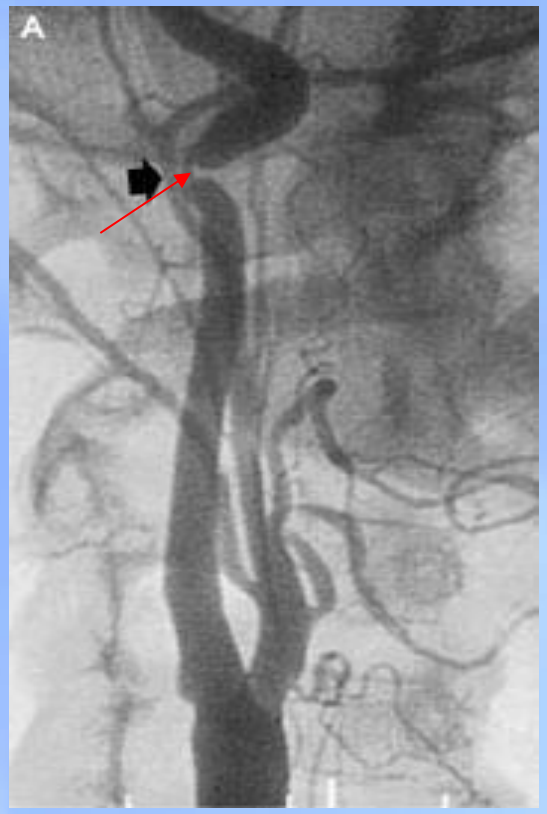

AS

脑血管肌纤维发育不良

鉴别诊断

FMD

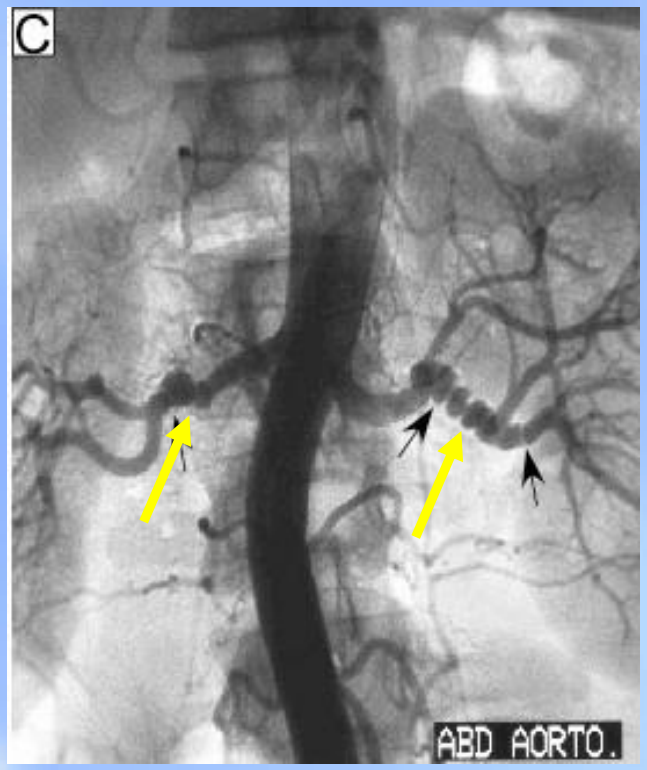

AS

脑血管肌纤维发育不良

FMD

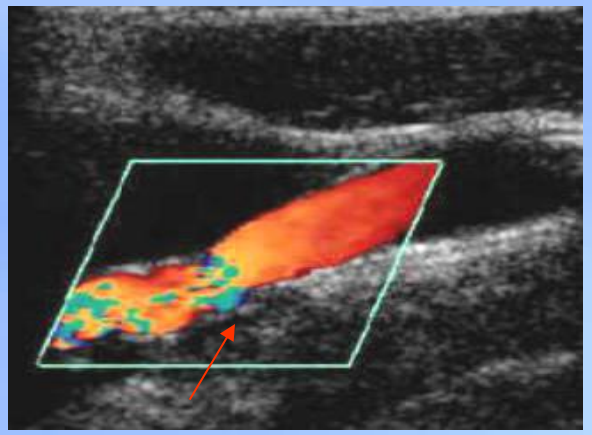

管腔不规则狭窄和扩张，在彩色血流的映衬下呈串珠样改变，狭窄处血流增快，见五彩血流信号

AS

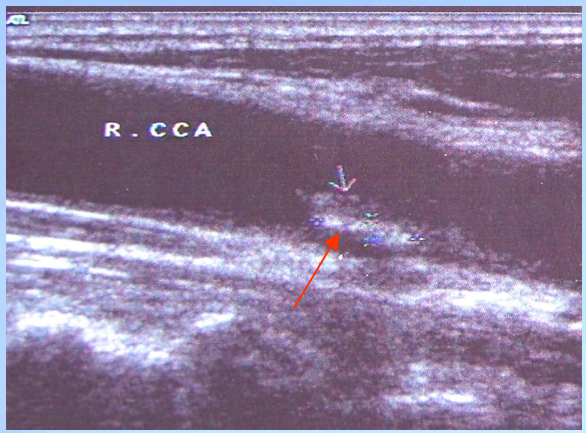

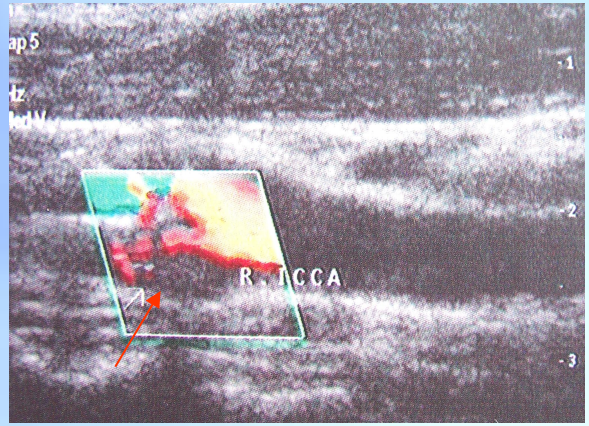

管壁正常结构消失，内膜不平，不规则增厚，见形态不一，大小不等粥样硬化斑块，狭窄处见五彩血流信号

脑血管肌纤维发育不良

FMD

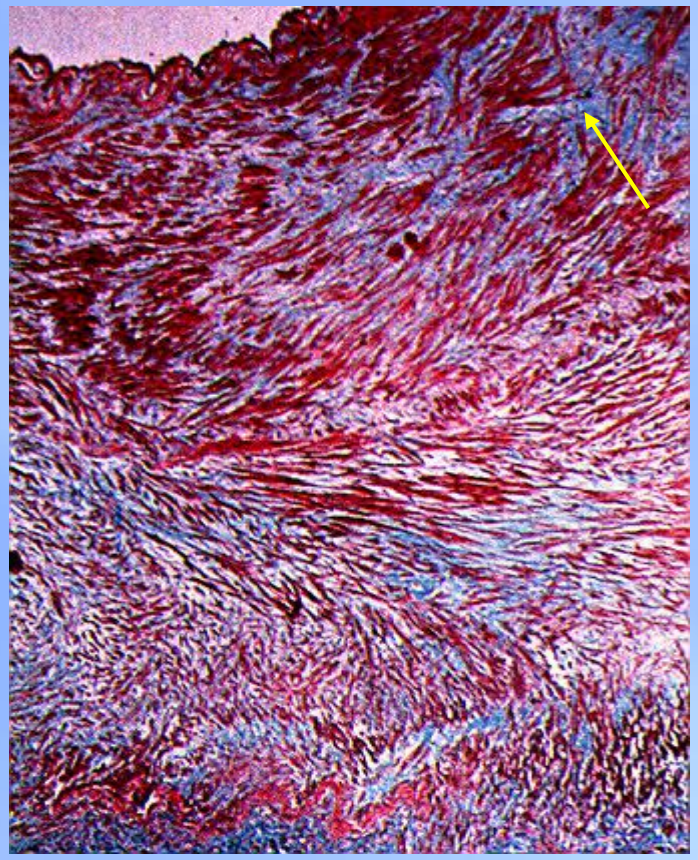

A cause of renal artery stenosis, In this trichrome stain there is excess collagen (blue) throughout the thickened media.

AS

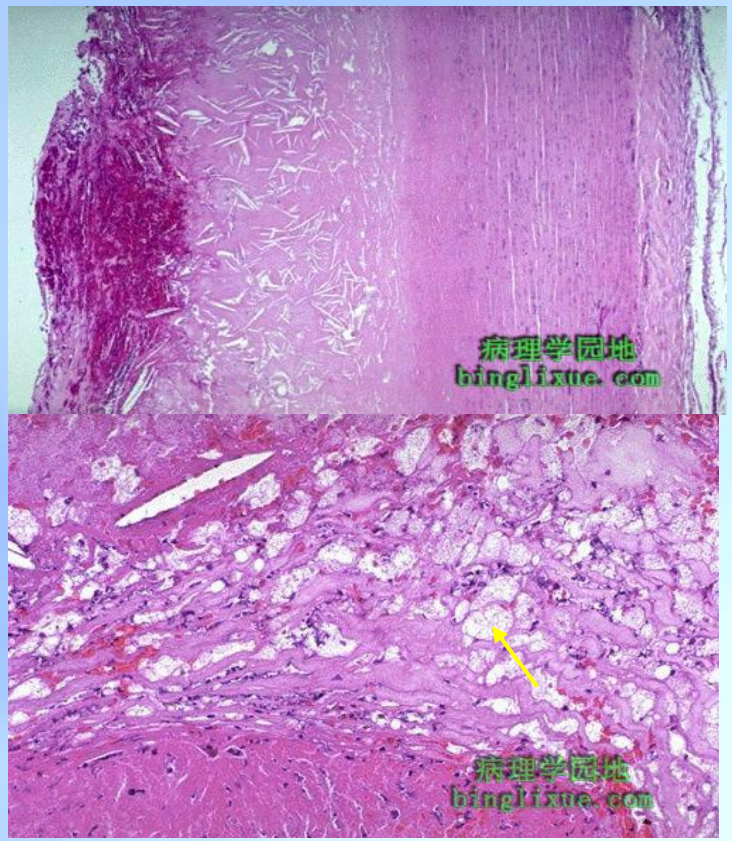

上图：动脉粥样斑块比残存的动脉中膜要厚。可见大量针状的胆固醇结晶（针状空隙），左边有新鲜出血。下图：高倍镜下可见粥样斑块中有许多泡沫细胞和胆固醇结晶。

脑血管肌纤维发育不良

鉴别诊断

大动脉炎

其他

脑血管肌纤维发育不良

治疗

1. 抗血小板聚集药物
2. 抗凝药物
3. 手术治疗
4. 血管内支架成形术

脑血管肌纤维发育不良

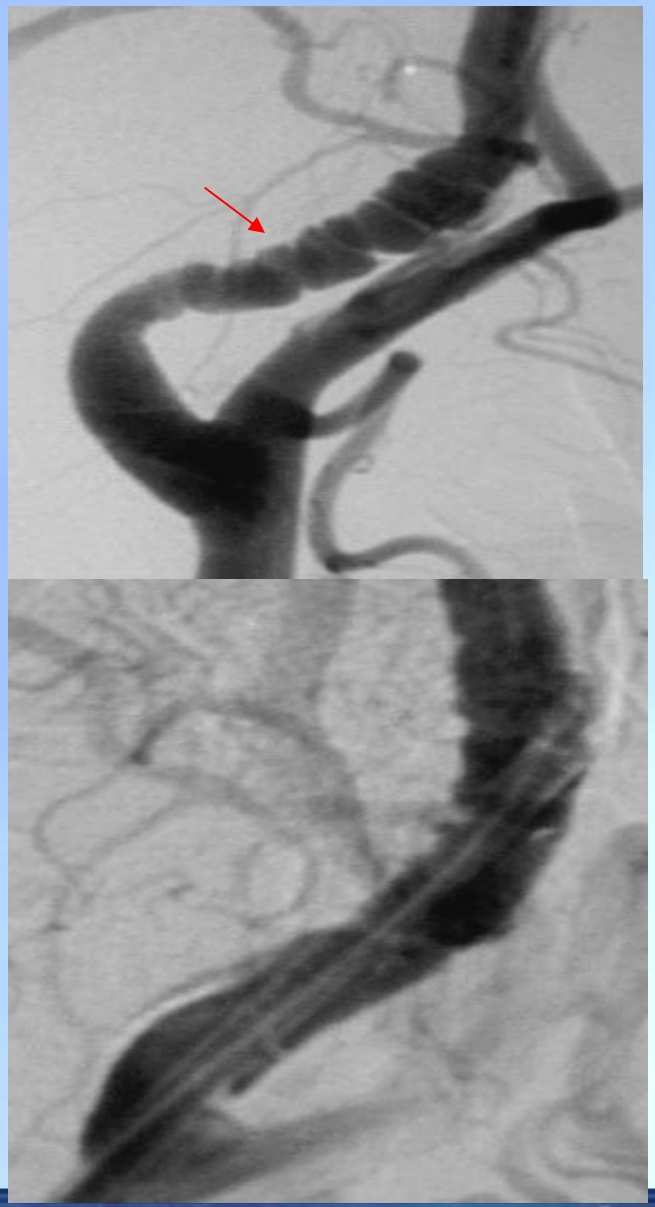

病例1 Carotid Arteriography in a Patient with Transient Ischemic Attacks.

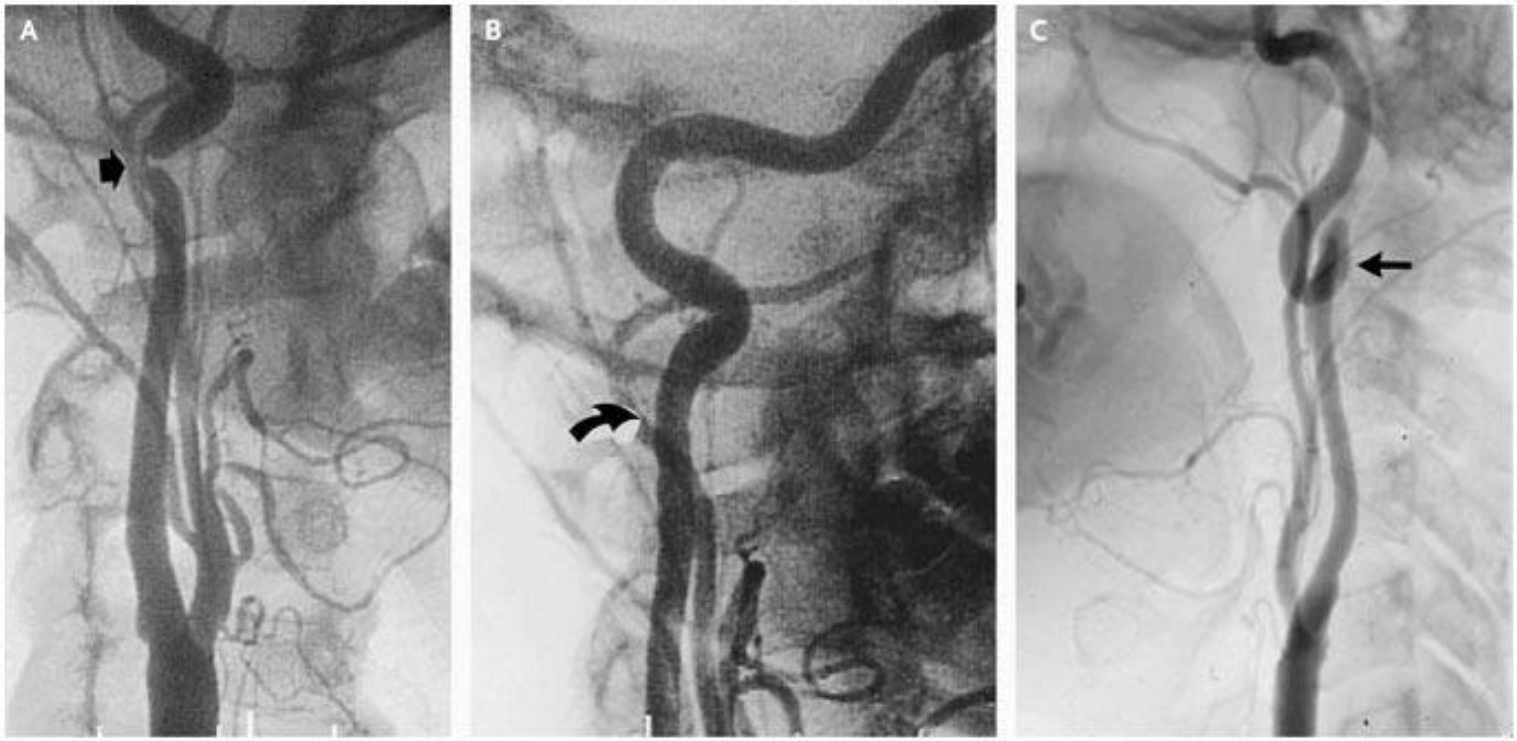

R-ICA R-ICA L-ICA

病例1

The arteriogram in Panel A was obtained at presentation; it shows a severe concentric stenosis in the distal internal carotid artery (arrow) in a 36-year-old female patient with a right hemispheric transient ischemic attack (left hemiparesis). This angiographic appearance is typical of intimal fibroplasia. After percutaneous balloon angioplasty, the internal carotid artery had a normal appearance on angiography (Panel B, arrow). Several months later, this patient had several left hemispheric transient ischemic attacks (aphasia and right-sided weakness). The left carotid arteriogram (Panel C) shows a severe redundancy (arrow) and a kink (not demonstrated in this view) in the distal internal carotid artery. This lesion was resected with an end-to-end anastomosis. The pathological features were typical of intimal fibromuscular dysplasia.

脑血管肌纤维发育不良

病例2

- A 50-year-old female without significant risk factors for CAD
- pressure-like chest discomfort
- radiating to her neck and jaw, while walking.
- ECG demonstrated ST-segment elevation in leads II, III, aVF and V3–V5, with reciprocal changes in leads I and aVL.

病例2

- intermittent ventricular bigeminy and accelerated junctional rhythm.
- Echocardiography confirmed localized apical and inferior-posterior wall hypokinesis
- left ventricular ejection fraction of 50–60%.

病例2

Cardiac catheterization demonstrated normal coronary arteries except for a 90% long diffuse lesion in the mid-LAD

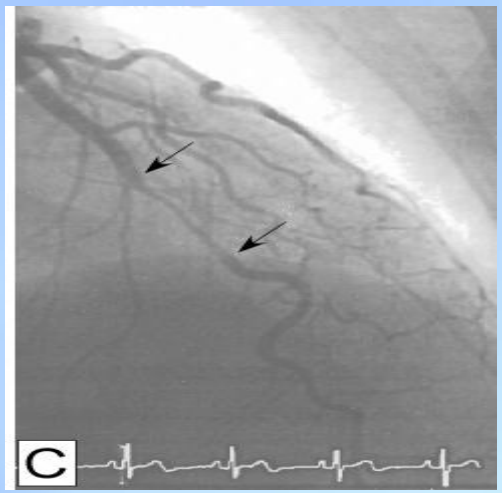

Representative angiograms of fibro-muscular dysplasia. (A) Right femoral angiogram; (C) Renal angiogram (arrows mark the “string of beads” pattern).

脑血管肌纤维发育不良

谢谢

南昌大学第二附属医院
THE HOSPITAL AFFILIATED OF NNACHANG UNIVERSITY

南昌大学第二附属医院神经内科