特殊病例分析

刘昊

南昌大学第二附属医院神经内科

病例

- 男性，85岁，突发性头疼5天
- 头疼呈间歇性，有中间搏动感，以前额为剧，没有加剧或减轻的诱发因素
- 既往无类似病史
- **既往史**：慢性肾功能不全、
  高血压、
  慢性充血性心力衰竭、
  阵发性心房颤动。

病例

- **入院体检**：

  颅神经未见异常，

  眼底检查见视神经斑，边界清晰。

  心脏听诊发现心律不齐。

- **实验室检查**：

  WBC13×109/L

  中性粒细胞0.78，淋巴细胞0.12.

  颅脑CT未见异常。

急诊给予患者一般镇痛治疗和观察。

病例

- **2d后**

  患者因前额持续性疼痛第2次就诊

  详细体检仍未发见阳性体征

  继续给予镇痛治疗

- **1d后**

  患者又以“前额痛累及颈背部”再次到急诊科，

  体检仍未发现异常，

  仍予镇痛药物治疗。

病例

- **2周后**

患者以双眼球后、眼周以及前额痛就诊

发现轻度喉炎，无鼻窦压痛。

初步拟诊为鼻窦炎引起的头痛，

给予鼻腔内滴注激素治疗。

病例

- 但在**同一 天**患者再次就诊

  主诉持续性眼球后、眼周剧痛，以右侧为剧

  体检仍为阴性，

  拟诊为不典型丛集性头痛。

给予对症治疗

病例

- **11天后**

患者以右眼失明就诊，

头痛局限于右眼，为轻度刺痛

无发热无恶心呕吐

眼科检查：结合膜清晰，无水肿，右眼底视乳头水肿，右眼视力丧失

眼底镜检查:视盘水肿苍白，血管阻塞,黄斑片状出血，动：静脉比为1：3

病例

实验室检查:

血液WBC11×109/L，

中粒性细胞0.75，淋巴细胞0.12，

红细胞沉降率为58mm/1h

C反应蛋白为 122mg/L

病例

病理：

颞浅动脉活检证实为**巨细胞动脉炎**

巨细胞动脉 炎（Giant Cell Arteritis ）

南昌大学第二附属医院神经内科

Giant Cell Arteritis

- 概念
- 流行病学、病因学
- 病理学
- 临床表现
- 辅助检查
- 诊断及鉴别诊断
- 治疗
- 典型病例

Giant Cell Arteritis

- 概念
- 流行病学、病因学
- 病理学
- 临床表现
- 辅助检查
- 诊断及鉴别诊断
- 治疗
- 典型病例

巨细胞动脉炎（giant cell arteritis GCA）

- 1890年由Hutchinon首次报道
- 一种原因不明的系统性坏死性血管炎
- 血管病变常呈节段性、多灶性
- 主要累及主动脉弓起始部的动脉分支
- 亦可累及主动脉的远端动脉，以及中小动脉
- 典型患者呈颞部头痛，头皮及颞动脉触痛，因而又称为颞动脉炎（Temporal Arteritis）

Giant Cell Arteritis

- 概念
- 流行病学、病因学
- 病理学
- 临床表现
- 辅助检查
- 诊断及鉴别诊断
- 治疗
- 典型病例

流行病学

- 多发于中老年人（>50岁）
- 女性发病高于男性 （60-75%为女性）
- 显著的地域分布

  欧白种人中常见（15 - 30/10万）

  少见于黑人和亚洲人

病因学

- 病因不明
- 遗传

  HLA-DR4、HLA-CW 、TNF—a2
- 内分泌
- 自身免疫

Giant Cell Arteritis

- 概念
- 流行病学、病因学
- **病理学**
- 临床表现
- 辅助检查
- 诊断及鉴别诊断
- 治疗
- 典型病例

病理学

- 炎性细胞浸润动脉壁
- 主要由T淋巴细胞和巨噬细胞构成，无B淋巴细胞浸润
- 研究显示炎性细胞常为节段性、跳跃性分布，可弥漫存在或形成典型的肉芽肿
- 主要累及内膜与中膜交界处
- 有研究发现在血管外膜炎性细胞浸润明显
- 动脉周围组织有炎性细胞浸润和小血管炎的表现

Giant Cell Arteritis

病理学

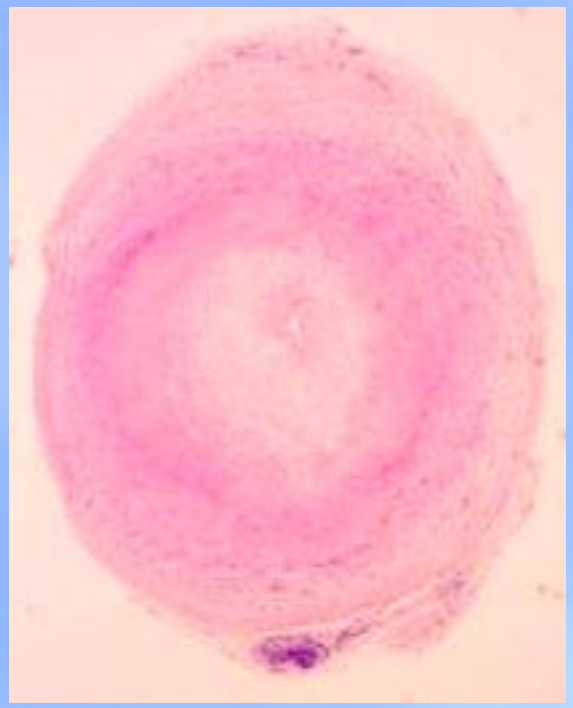

Low-power view of a temporal artery biopsy sample shows giant cell arteritis.

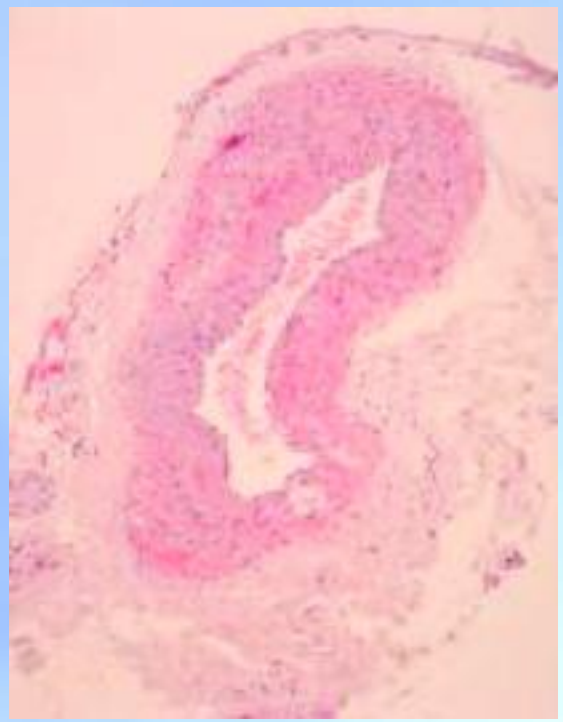

Low-power view of a normal temporal artery biopsy sample for comparison with Image 1

病理学

High-power view shows disruption of the intima with a collection of multinucleated giant cells.

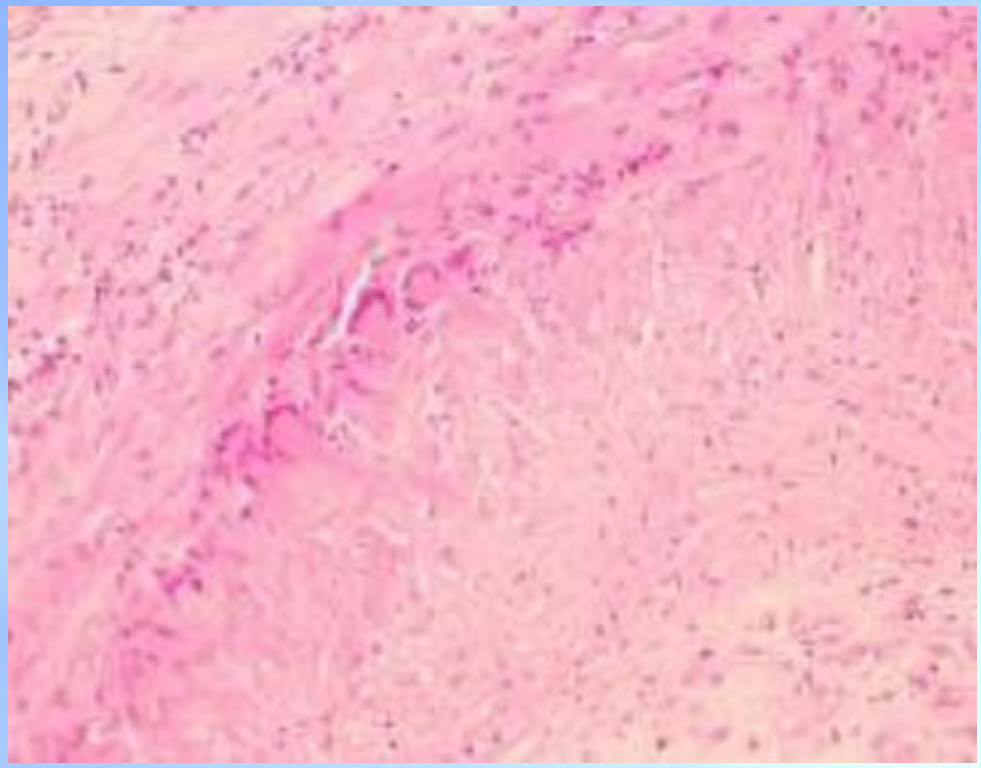

病理学

This low power view of a cross-section of a temporal artery shows an inflammatory infiltrate in the media and intimal fibrosis. The thickening of the media and the lumenal narrowing caused by the intimal fibrosis account for the ischemic changes that give rise to clinical symptoms. Although the temporal artery is the vessel most frequently affected, other small and medium arteries of the body may be involved. Involvement of the ophthalmic artery can result in loss of vision.

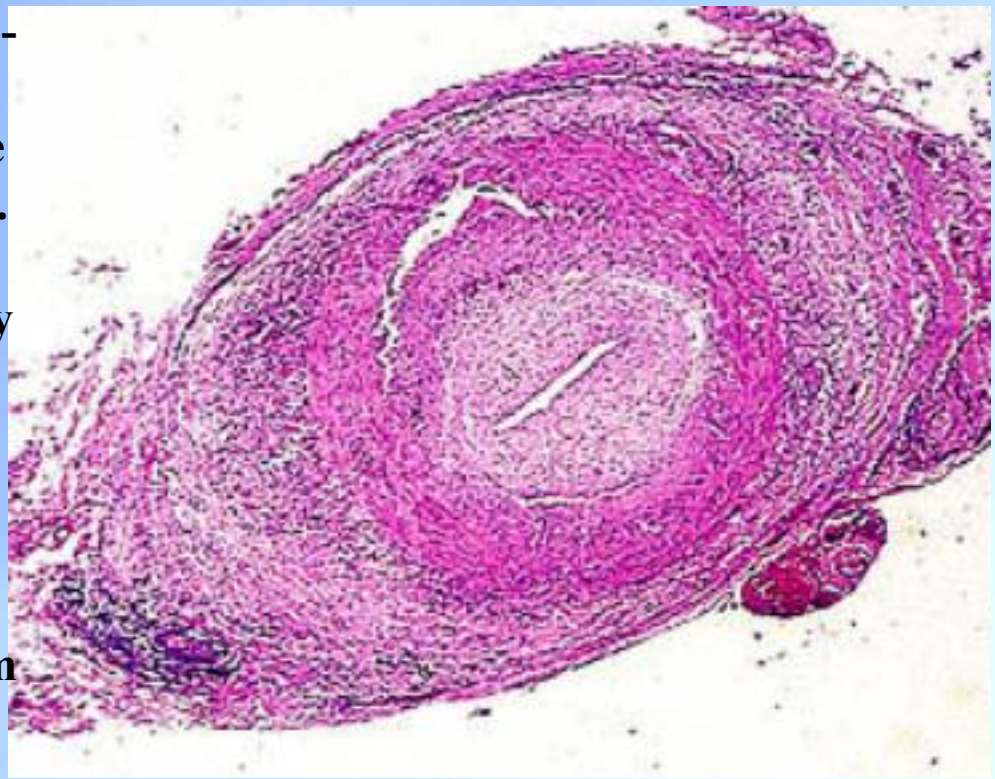

病理学

Higher power view showing the intimal fibrosis and infiltration of the media by inflammatory cells, chiefly lymphocytes and eosinophils. There is an irregular disruption of the media at the level of the internal elastica. In this area, there are two or three multinucleated giant cells. Giant cells are part of the inflammatory infiltrate in most, but not all cases of this form of vasculitis.

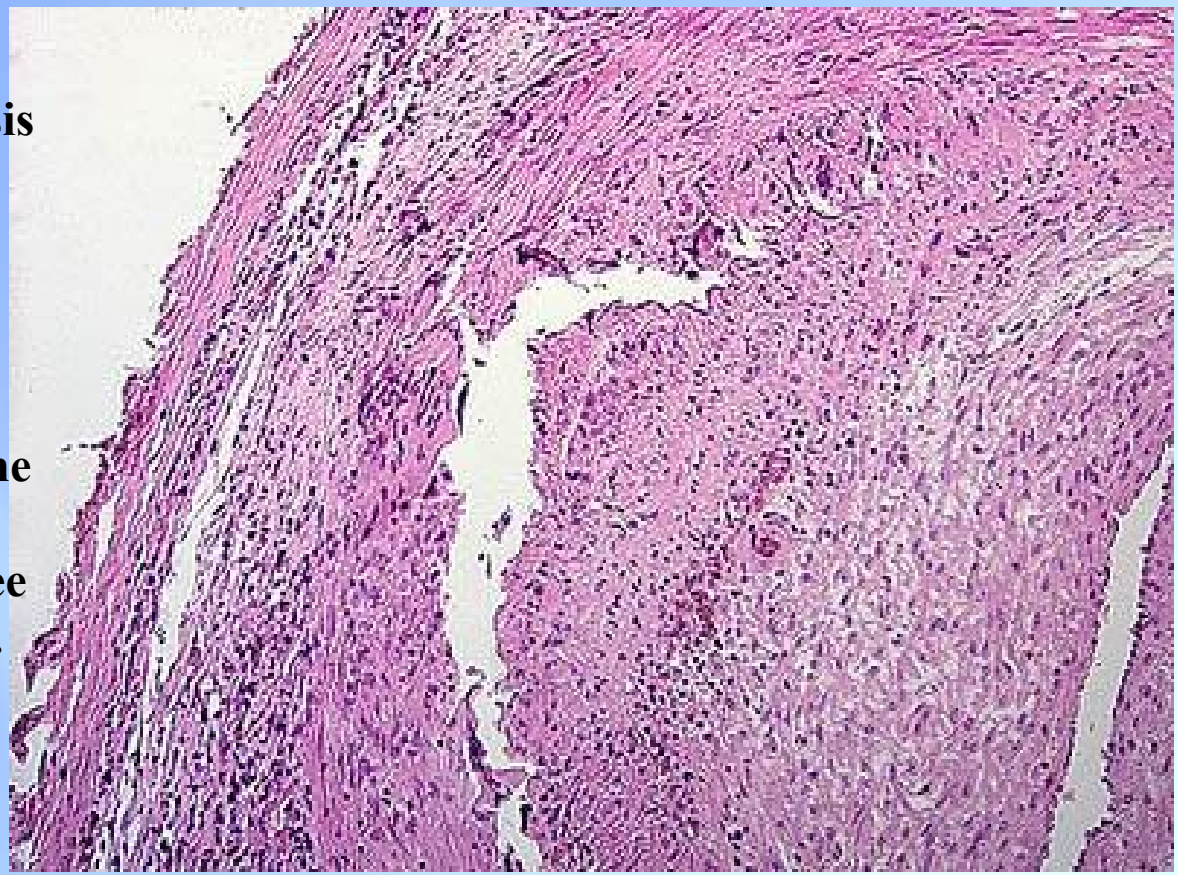

病理学

This figure is a high power view of a biopsy of a temporal artery in a subject with temporal arteritis. The black arrow demonstrates the endothelium with red blood cells in the intravascular space. The endothelium shows pathologic changes with edema and a proliferative subintimal response. The yellow arrow points out the disrupted elastic lamina and the blue arrow a granuloma typical of this form of large vessel vasculitis.

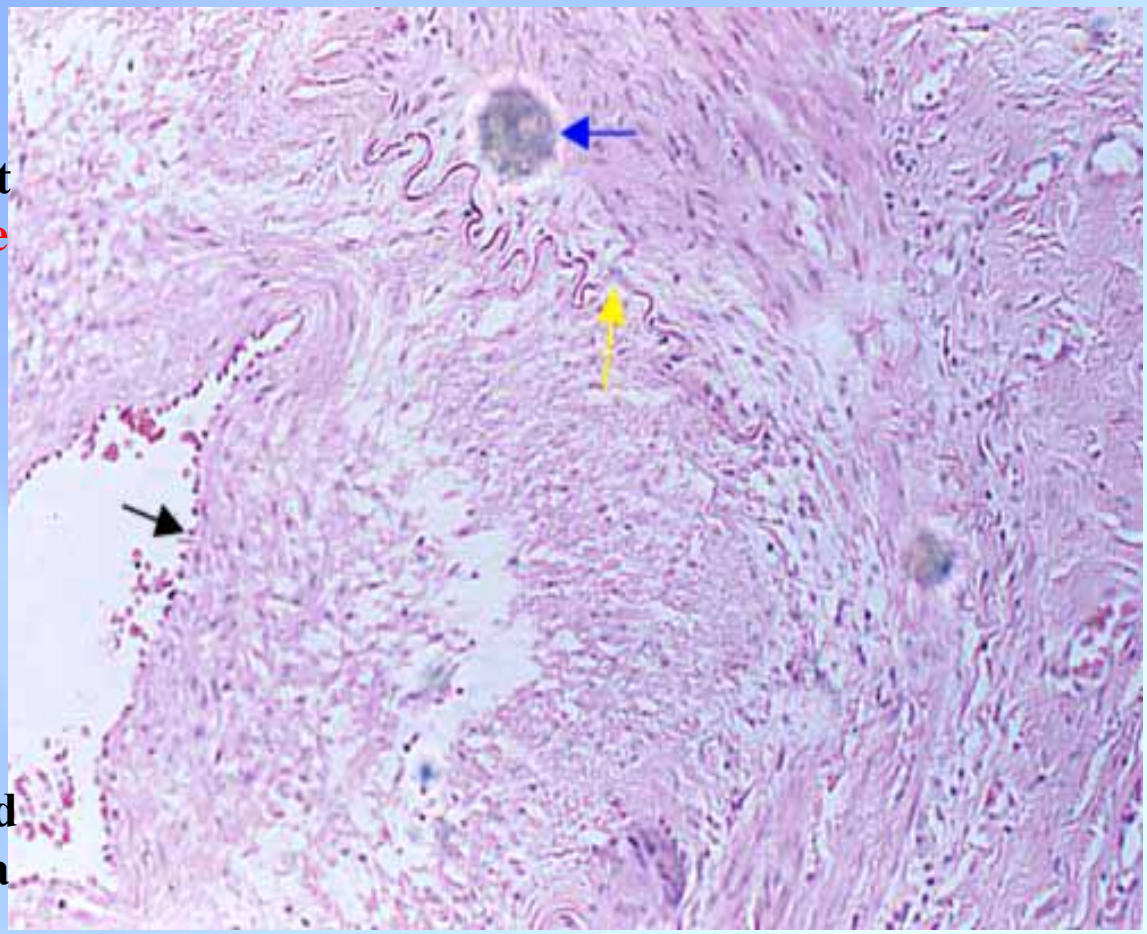

病理学

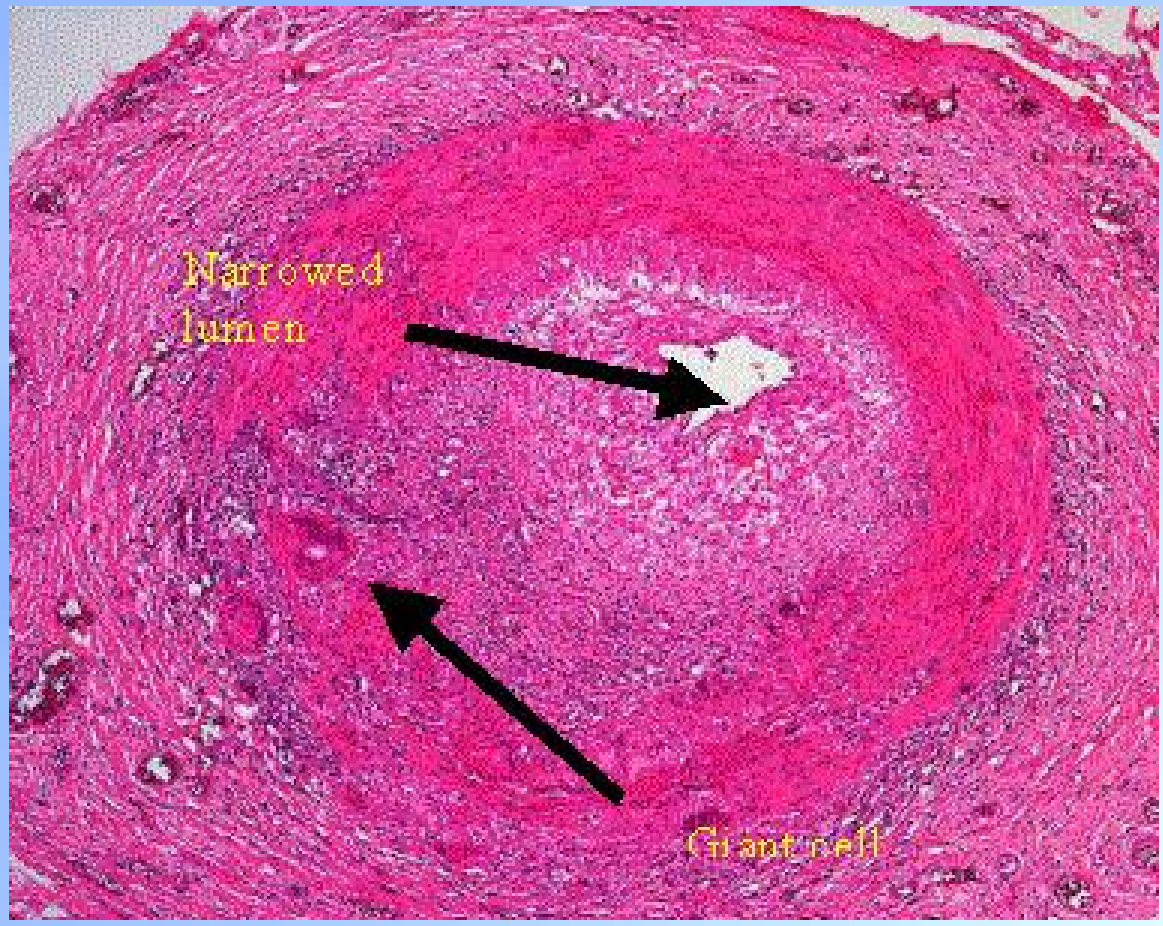

病理学

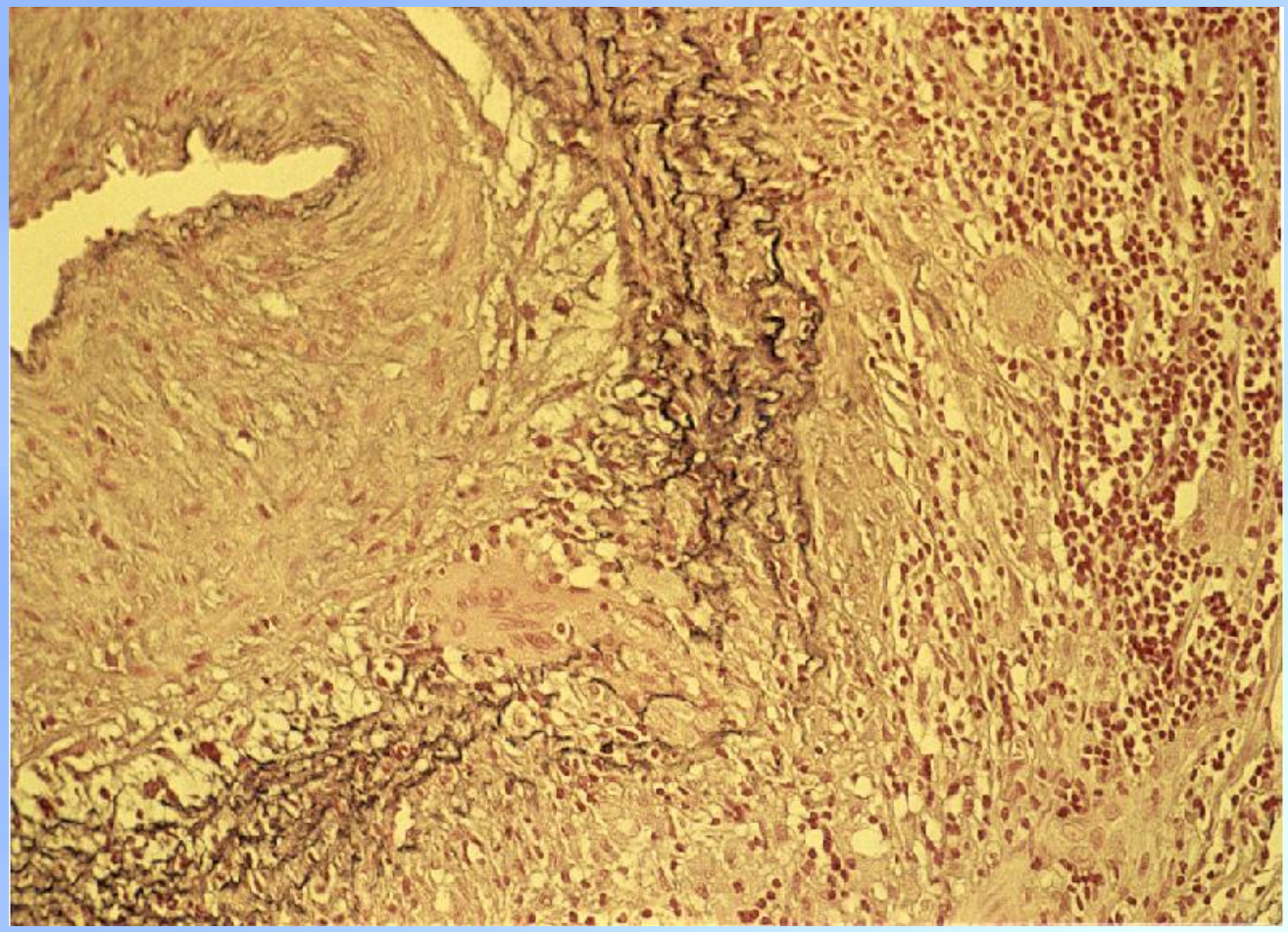

histology of temporal arteritis

Giant Cell Arteritis

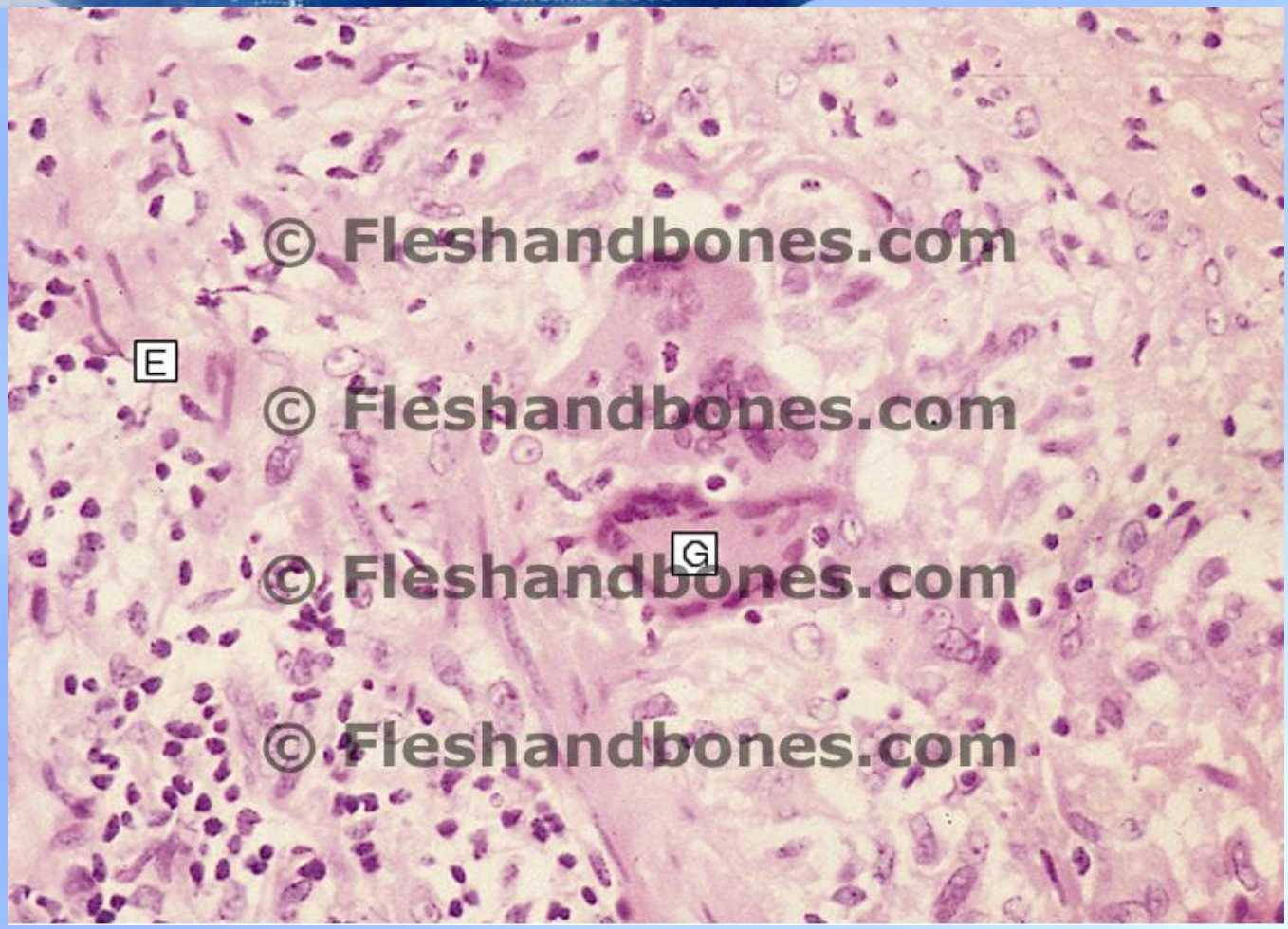

In giant cell arteritis the vessel wall is thickened and infiltrated by a mixture of inflammatory cells. This is largely composed of T-lymphocytes, but has foci of histiocytes and giant cells (G). The histiocytic giant cells are mainly related to fragments of the disrupted elastic lamina (E). Complication by thrombosis is common.

Giant Cell Arteritis

- 概念
- 流行病学、病因学
- 病理学
- 临床表现
- 辅助检查
- 诊断及鉴别诊断
- 治疗
- 典型病例

临床表现

表 1　20例巨细胞动脉炎患者的临床特征

临床变量	数目或平均值	%或范围
发病年龄(岁)	48.7±10.7	20～73
男性:女性(例)	17:3	
活检前症状持续时间(周)	48.0±149.7	1～676
活检前已用过类固醇激素(例)	4	20.0
新近出现的头痛(例)	18	90.0
颞动脉异常*(例)	17	85.0
视觉异常**(例)	9	45.0
发热(例)	7	35.0
眼睑下垂(例)	4	20.0
风湿性多肌痛(例)	4	20.0
头昏(例)	3	15.0
轻偏瘫(例)	3	15.0
失眠(例)	3	15.5
易疲劳(例)	2	10.0
下颌关节间歇性乏力(例)	2	10.0
晕厥(例)	2	10.0
咳嗽(例)	1	5.0
呕吐(例)	1	5.0
癫痫(例)	1	5.0
升高的 ESR***(例)	13	65.0
血尿(例)	1	5.0
C反应蛋白异常(例)	5/15	25.0
类风湿因子异常(例)	0	0.0
抗核抗体阳性(例)	0	0.0
血糖升高(例)	1	5.0

注:*颞动脉变粗,搏动减弱或消失,触痛或者炎性体征;**视物模糊,复视,失明,瞳孔散大;***红细胞沉降率

临床表现

TABLE 1
Initial Manifestations and Clinical Findings in 100 Patients with Temporal Arteritis

	Number of patients	
Symptom or complaint	**Presenting symptom**	**Finding at diagnosis**
Headache	32	68
Polymyalgia rheumatica	25	39
Fever	15	42
Visual symptoms without loss of vision	7	30
Weakness, malaise, fatigue	5	40
Tenderness over arteries	5	27
Myalgias	4	30
Weight loss, anorexia	2	50
Jaw claudication	2	45
Permanent loss of vision	1	14
Tongue claudication	1	6
Sore throat	1	9
Vasculitis on angiogram	1	NA
Stiffness of hands and wrists	1	NA
Decreased temporal artery pulse	NA	46
Erythematous, nodular, swollen arteries	NA	23
Central nervous system abnormalities	NA	15
Synovitis	NA	NA
Dysphagia	NA	15
Limb claudication	NA	NA

NA = not available.
Adapted with permission from Hunder GG. Temporal arteritis and polymyalgia rheumatica. In: Kelley WN, et al. Textbook of rheumatology. 4th ed. Philadelphia: Saunders, 1993:103-12.

Giant Cell Arteritis

南昌大学第二附属医院
THE HOSPITAL AFFILIATED OF NNACHANG UNIVERSITY

临床表现

全身症状：

非特异性(乏力、纳差、体重减轻及低热)

临床表现

器官受累症状：

头部：头痛最常见

新近发生的、偏侧/双侧/枕后部剧烈疼痛

刀割样/烧灼样/持续性胀痛

伴有头皮触压痛/可触及的痛性结节

头皮结节沿颞动脉走向分布，具有诊断价值

头痛可持续性也可间歇性发作

头痛剧烈程度与血管炎严重程度不一定一致

典型的颞动脉受累表现为动脉屈曲、怒张、搏动增强，也可因血管闭塞搏动消失。

Giant Cell Arteritis

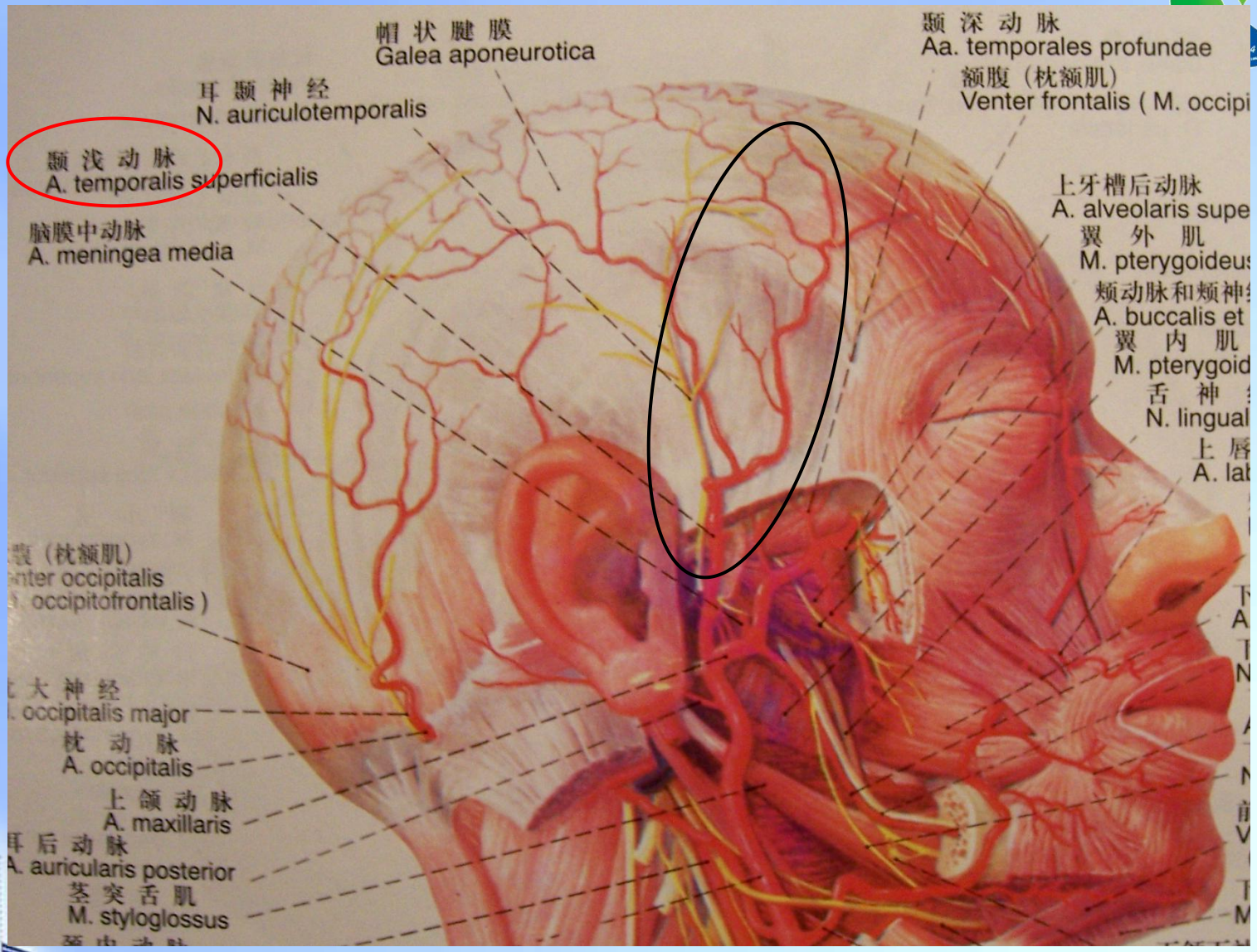

临床表现

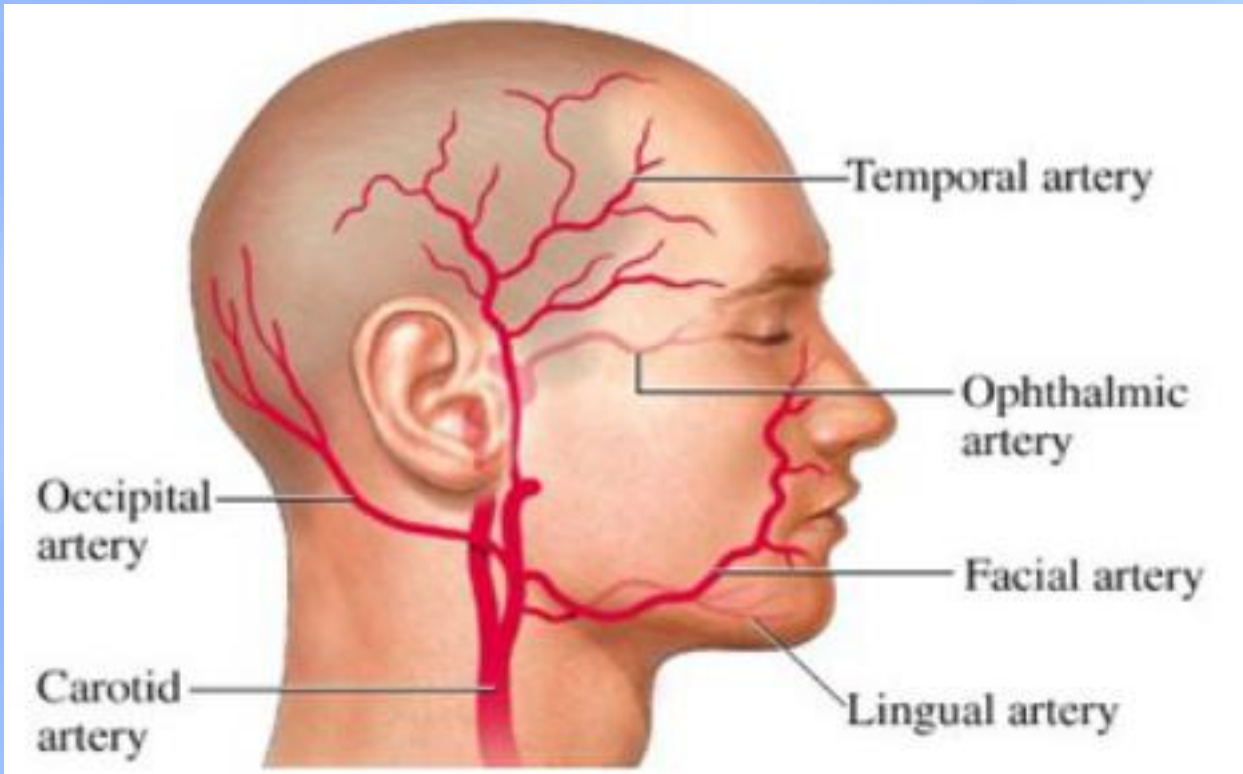

This diagram shows some of the arteries branching from the carotid arteries that are commonly affected in GCA. Notice that other affected arteries may include those originating from the aortic arch and are not shown in this image

临床表现

This photograph shows the swelling and thickening of the temporal artery in a GCA patient

临床表现

临床表现

眼部：

1. 黑蒙、视物不清、眼睑下垂、复视、部分失明或全盲
2. 眼动脉或后睫动脉受累引起缺血性视神经炎是失明的最常见原因
3. 中央视网膜动脉阻塞、动脉炎所致的枕部皮质梗死也可引起失明
4. 失明可以是初发症状，但一般出现在其它症状之后数周或数月

临床表现

眼部：

眼底检查：

1. 早期常为缺血性视神经炎。视乳头苍白、水肿；视网膜水肿，静脉曲张，可见绵絮样斑及小出血点。
2. 后期可见视神经萎缩等。

眼肌麻痹也较常见

有时可见到瞳孔不等大，或出现霍纳（Horner）征

临床表现

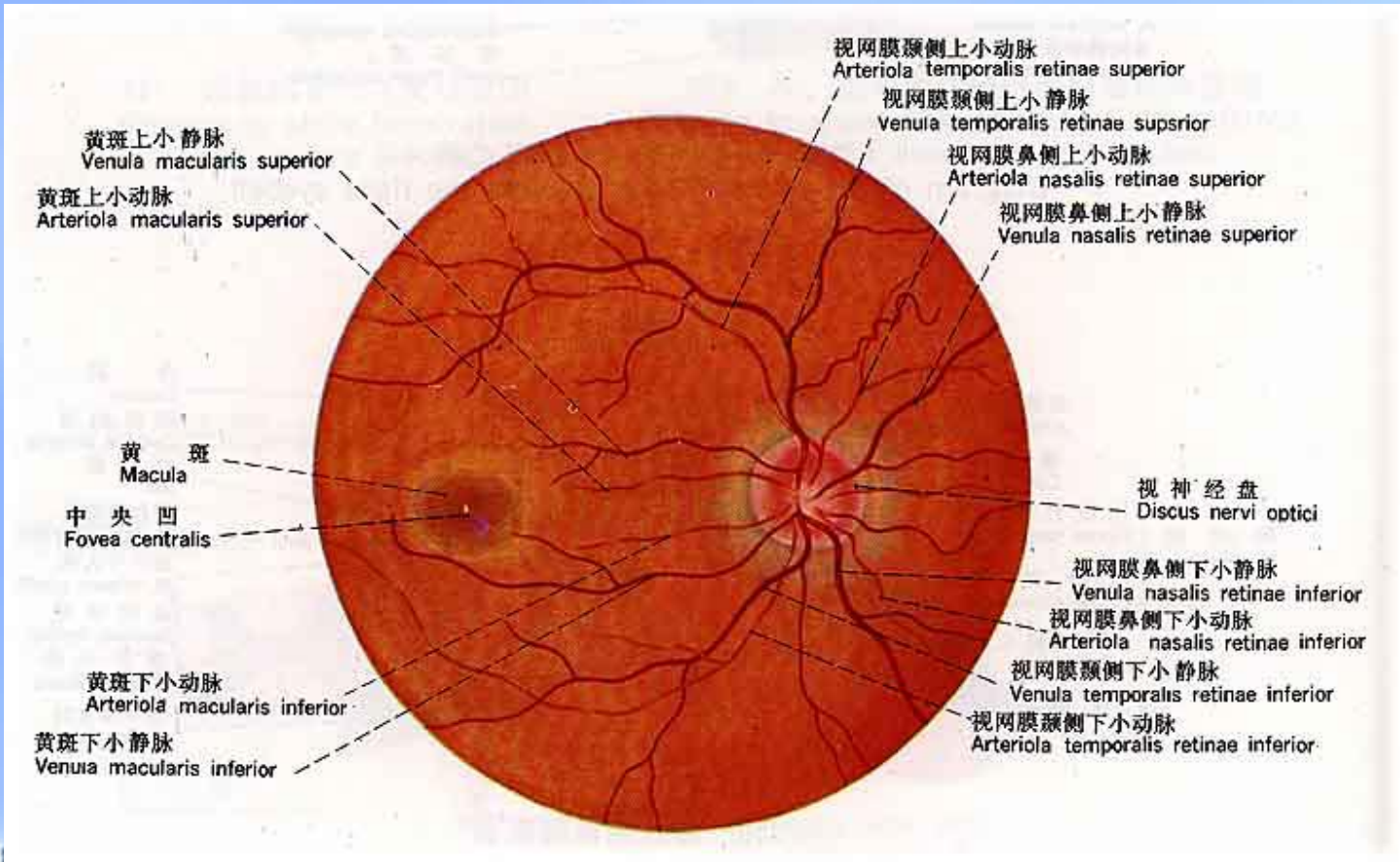
视网膜颞侧上小动脉
Arteriola temporalis retinae superior
视网膜颞侧上小静脉
Venula temporalis retinae supsrior
视网膜鼻侧上小动脉
Arteriola nasalis retinae superior
视网膜鼻侧上小静脉
Venula nasalis retinae superior
黄斑上小静脉
Venula macularis superior
黄斑上小动脉
Arteriola macularis superior
黄 斑
Macula
中 央 凹
Fovea centralis
视 神 经 盘
Discus nervi optici
视网膜鼻侧下小静脉
Venula nasalis retinae inferior
视网膜鼻侧下小动脉
Arteriola nasalis retinae inferior
视网膜颞侧下小静脉
Venula temporalis retinae inferior
视网膜颞侧下小动脉
Arteriola temporalis retinae inferior
黄斑下小动脉
Arteriola macularis inferior
黄斑下小静脉
Venua macularis inferior

正常眼底

临床表现

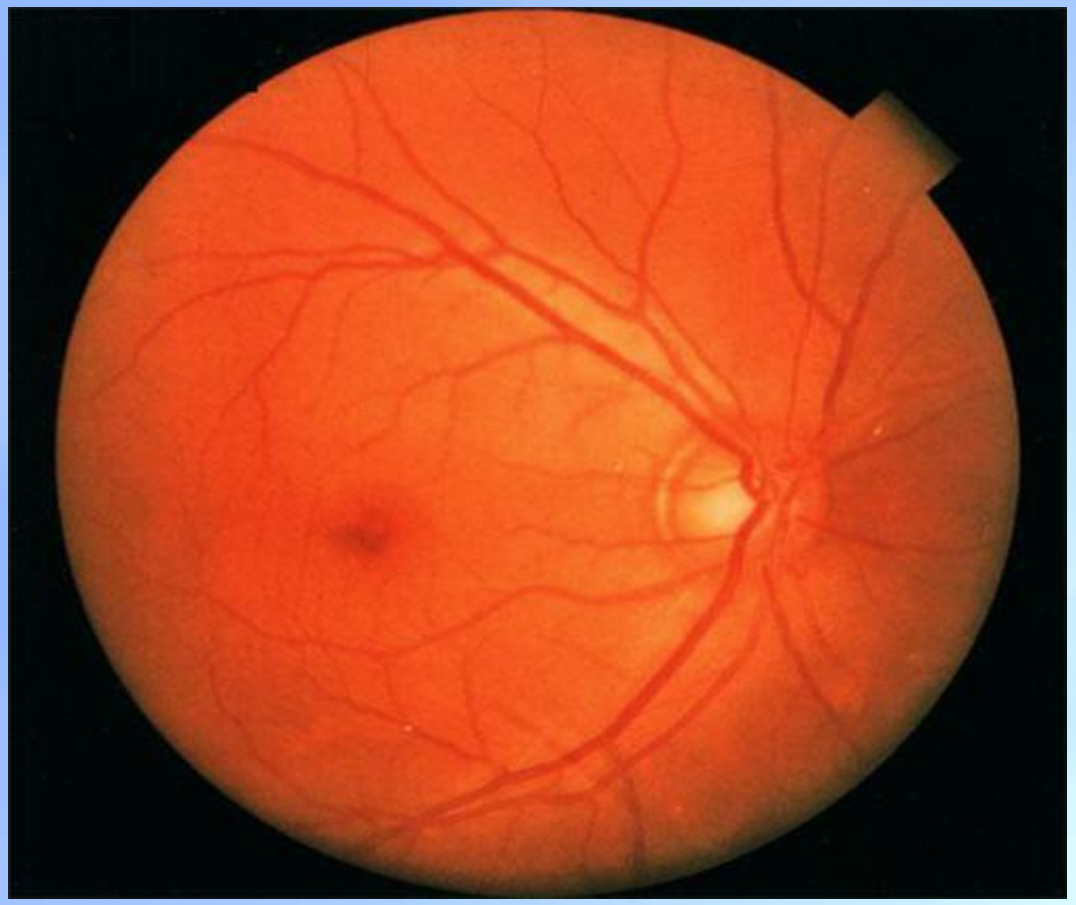

正常眼底

临床表现

Giant cell arteritis ischemic papillopthy
Optic Disc Atrophy with Special Features
- Atrophy with cupping

临床表现

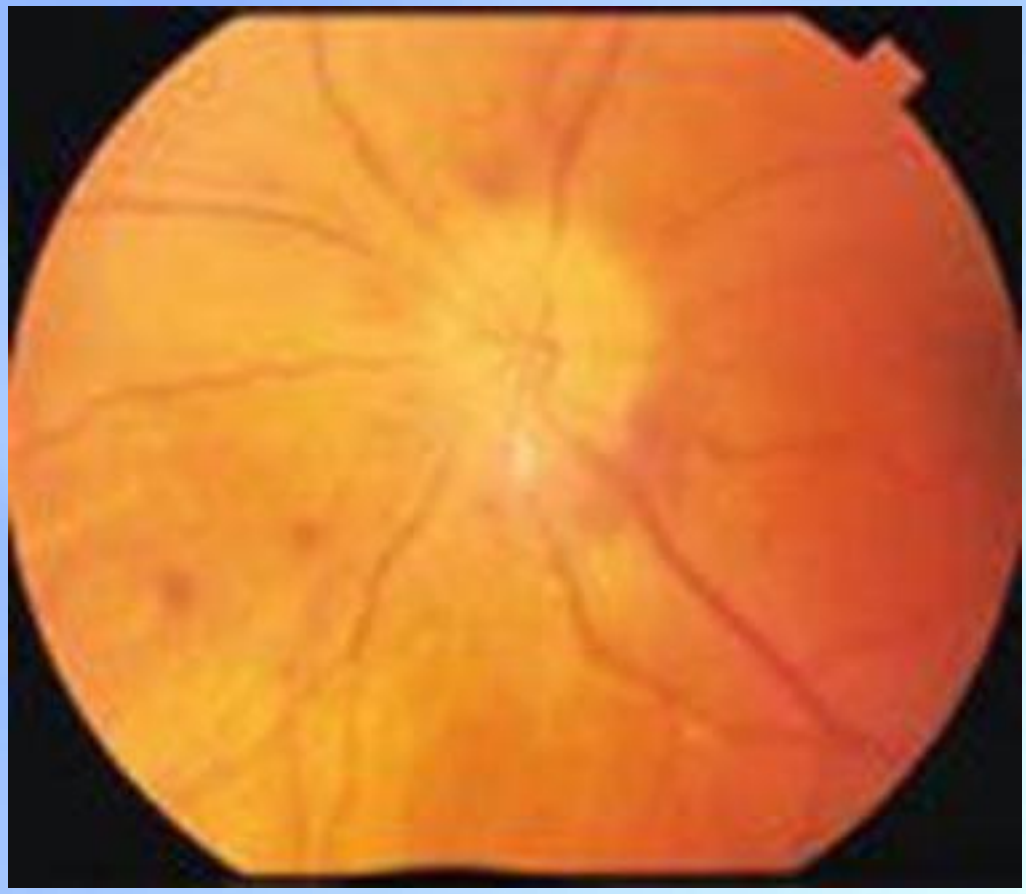

临床表现

Disc swelling. Giant Cell Arteritis. Temporal. Ischemic swelling. Blind eye with pallid swelling and marked dilation of central retinal vein.

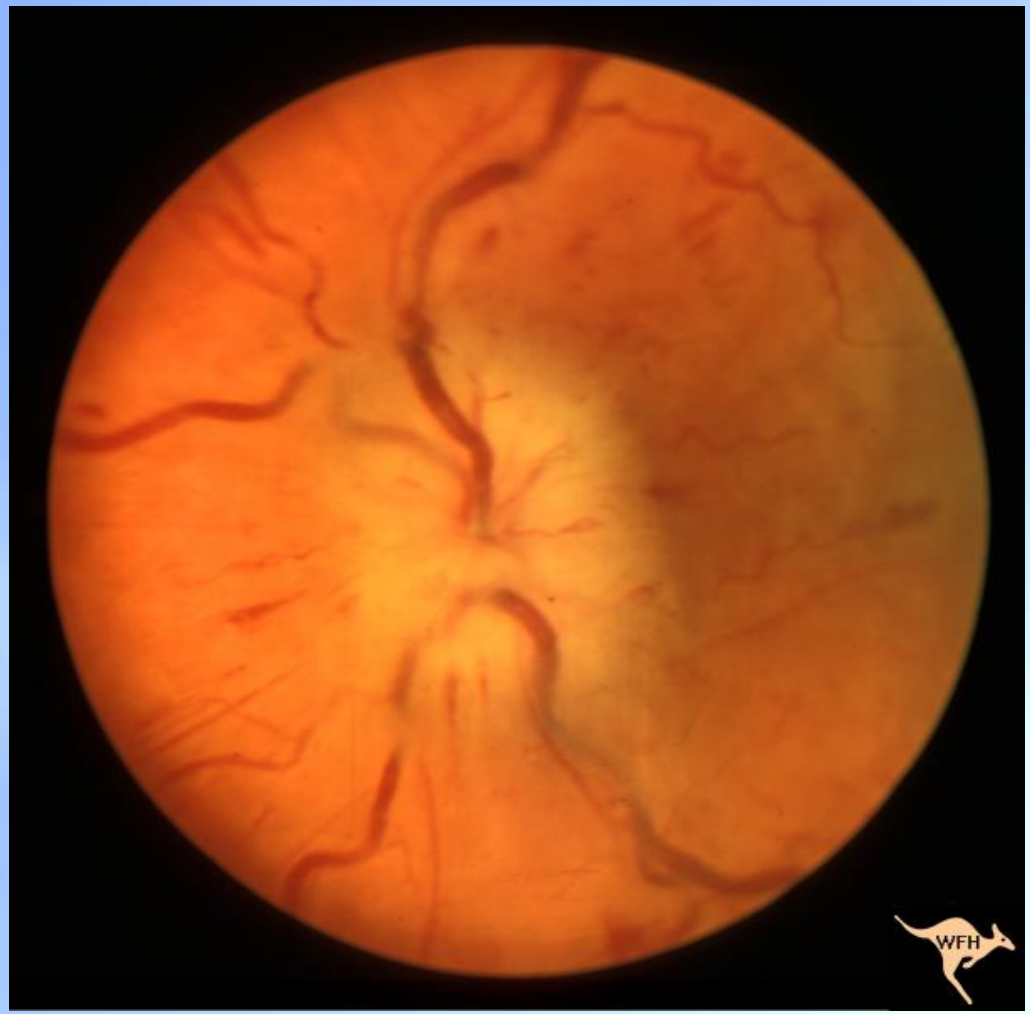

临床表现

间歇性运动障碍:

1. 2/3患者因面动脉炎，局部血供不良，引致下颌肌痉挛
2. 间歇性咀嚼不适、咀嚼疼痛、咀嚼停顿和下颌偏斜等
3. 舌肌运动障碍出现吞咽困难、味觉迟钝
4. 间歇性运动障碍也可影响到四肢，表现为间歇性跛行、上肢活动不良

临床表现

神经系统表现：

1. 30%患者出现多种神经系统症状
2. 颈动脉或椎动脉病变而出现发作性脑缺血、中风、偏瘫或脑血栓等，是GCA主要死因之一
3. 继发性神经病变(单神经炎、周围多神经炎、上、下肢末梢神经炎)

临床表现

心血管系统表现：(10~15%)

呼吸系统表现:(较少累及 10%)

持续性干咳、咽痛、声嘶

精神症状:抑郁或意识模糊

对称性关节滑膜炎很少见

Giant Cell Arteritis

- 概念
- 流行病学、病因学
- 病理学
- 临床表现
- **辅助检查**
- 诊断及鉴别诊断
- 治疗
- 典型病例

实验室检查：

- 轻到中度正细胞正色素性贫血，
  白细胞计数增高或正常
  血小板计数可增多。
- 活动期血沉增快（常高达100mm/hr）
  CRP增高
  约1%的患者血沉正常
- 白蛋白减少，多克隆高球蛋白血症和a2球蛋白增高，碱性磷酸酶可升高。
- 肌酶、肌电图、肌肉活检正常。

颞动脉活检：

- 诊断GCA的可靠手段，特异性100%
- 有触痛或有结节的部位，切取长度为2~3cm 连续病理切片
- 活检的阳性率仅在40~80%
- 活检阴性不能排除GCA诊断。

影像学检查：

彩超检查：

肉芽肿型

- 节段性/全血管性改变
- 血管迂曲，血管壁向心性增厚，回声明显减低
- 正常血管壁三层结构消失，血管腔明显狭窄或消失
- 血管内血流信号呈血管周边充盈缺损或消失，血管腔周围有一低回声“晕”

影像学检查：

Halo sign in colour duplex sonography examination in a patient with giant cell arteritis. Hypoechoic area around the temporal artery trunk in longitudinal (upper panel) and transverse (lower panel) views.

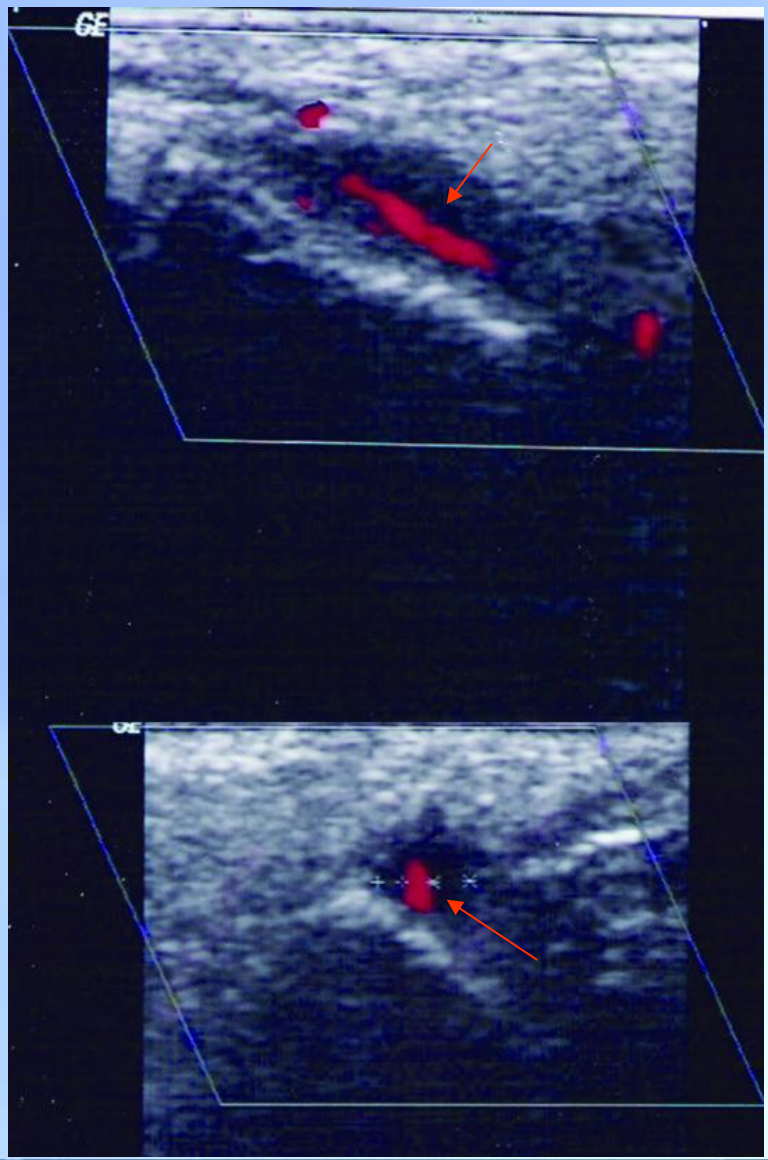

影像学检查：

彩超检查：

类动脉硬化型

- 类似于动脉硬化样改变
- 血管迂曲，管壁增厚，回声增强
- 内膜可测及强回声斑附着
- 病变血管与周围组织界限不清
- 血管狭窄程度与动脉炎所致血管壁增厚程度成正比

Giant Cell Arteritis

- 概念
- 流行病学、病因学
- 病理学
- 临床表现
- 辅助检查
- 诊断及鉴别诊断
- 治疗
- 典型病例

诊断标准：

目前采用1990年ACR巨细胞动脉炎分类标准：

（1） 发病年龄≥50岁 发病时年龄在50岁以上

（2） 新近出现的头痛 新近出现的或出现新类型的局限性头痛

（3） 颞动脉病变 颞动脉压痛或触痛、搏动减弱，除外颈动脉硬化所致。

诊断标准：

（4） 血沉增快 魏氏法测定红细胞沉降率≥50mm/h

（5） 动脉活检异常 活检标本示血管炎，其特点为单核细胞为主的炎性浸润或肉芽肿性炎症，常有多核巨细胞

符合上述五条标准中的至少三条可诊断

此标准的诊断敏感性和特异性分别是：93.5%和91.2%

鉴别诊断：

	GCA	AS	FMD
年龄	＞50	中老年	30 - 50
性别	女性多见	男性多见	女性多见
临床表现	头痛多见	神经系统缺血改变	神经系统缺血改变
脑血管危险因素	多无	多合并	多无
病变部位	主动脉弓起始部、远端动脉，以及中小动脉	血管近端	血管1/2 - 远端1/3
与正常血管分界	不清楚	介于GCA与FMD之间	清楚

鉴别诊断：

GCA

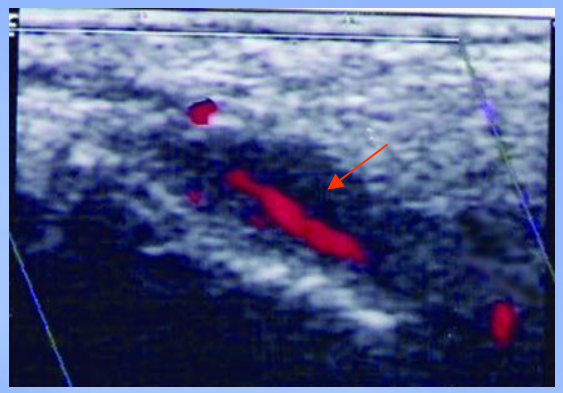

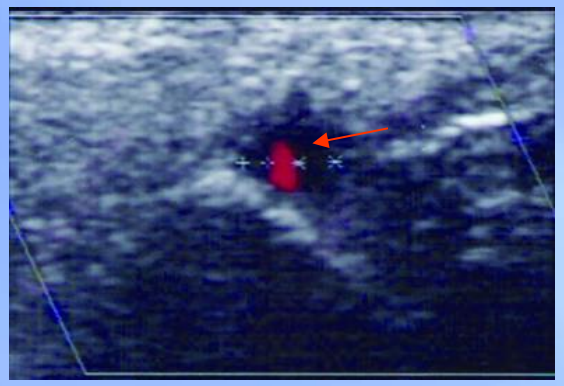

血管壁向心性增厚，回声明显减低。血管腔明显狭窄，血管内血流信号呈血管周边充盈缺损或消失，血管腔周围有一低回声“晕”

FMD

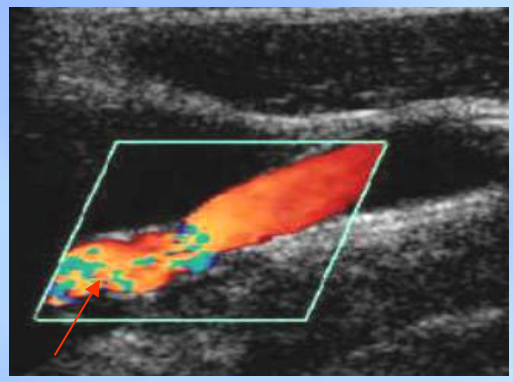

管腔不规则狭窄和扩张，在彩色血流的映衬下呈串珠样改变，狭窄处血流增快，见五彩血流信号

AS

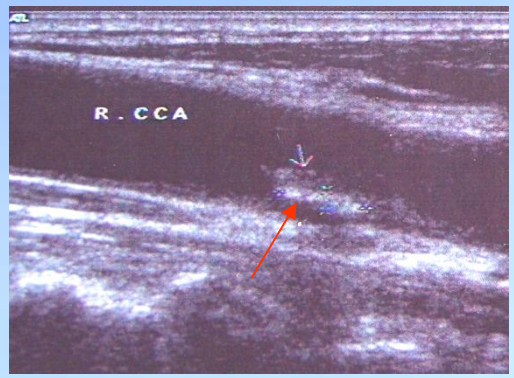

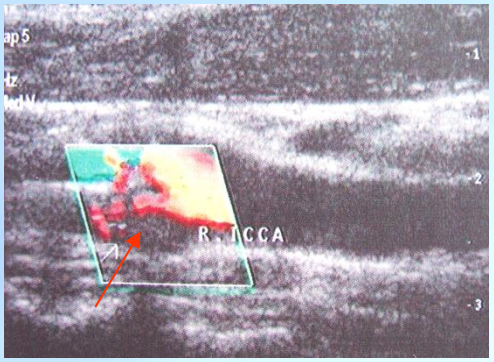

管壁正常结构消失，内膜不平，不规则增厚，见形态不一，大小不等粥样硬化斑块，狭窄处见五彩血流信号

鉴别诊断：

GCA

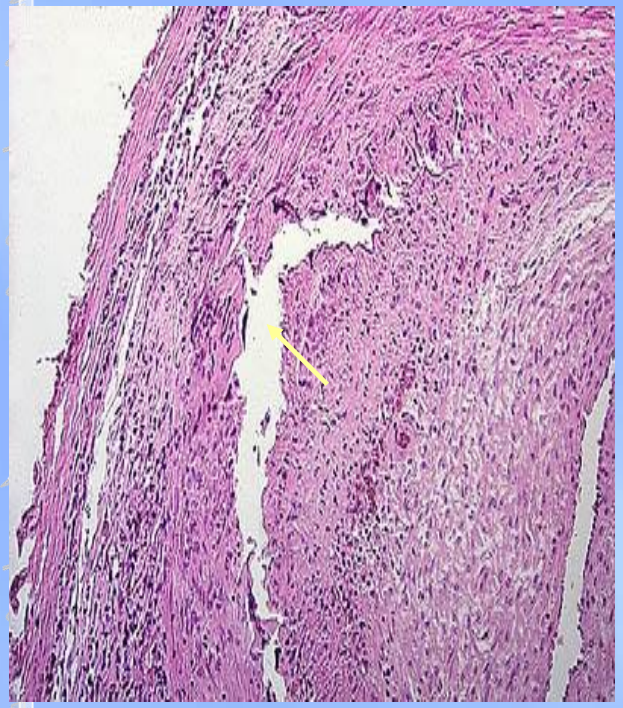

There is an irregular disruption of the media at the level of the internal elastica. In this area, there are two or three multinucleated giant cells.

FMD

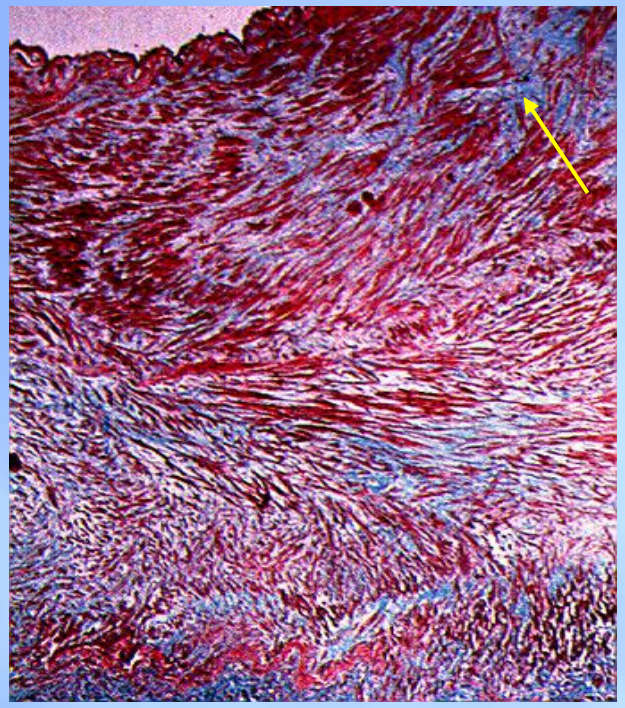

A cause of renal artery stenosis, In this trichrome stain there is excess collagen (blue) throughout the thickened media.

AS

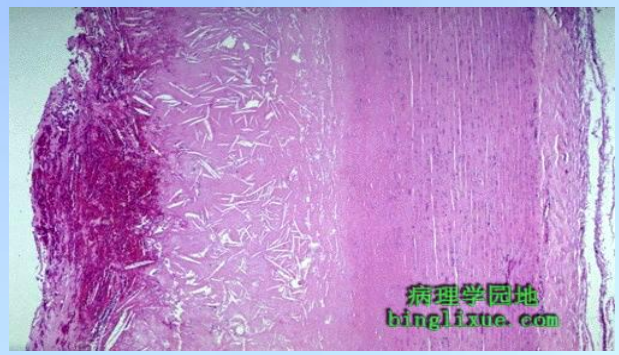

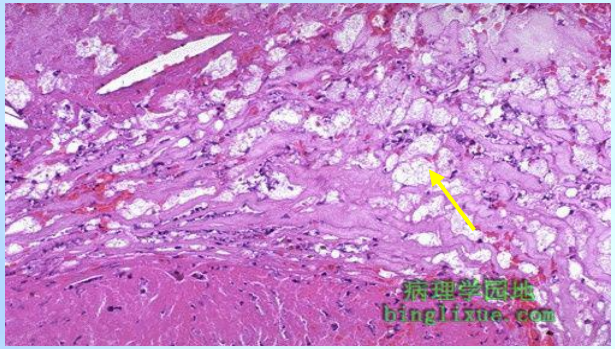

上图：动脉粥样斑块比残存的动脉中膜要厚。可见大量针状的胆固醇结晶（针状空隙），左边有新鲜出血。下图：高倍镜下可见粥样斑块中有许多泡沫细胞和胆固醇结晶。

Giant Cell Arteritis

鉴别诊断：

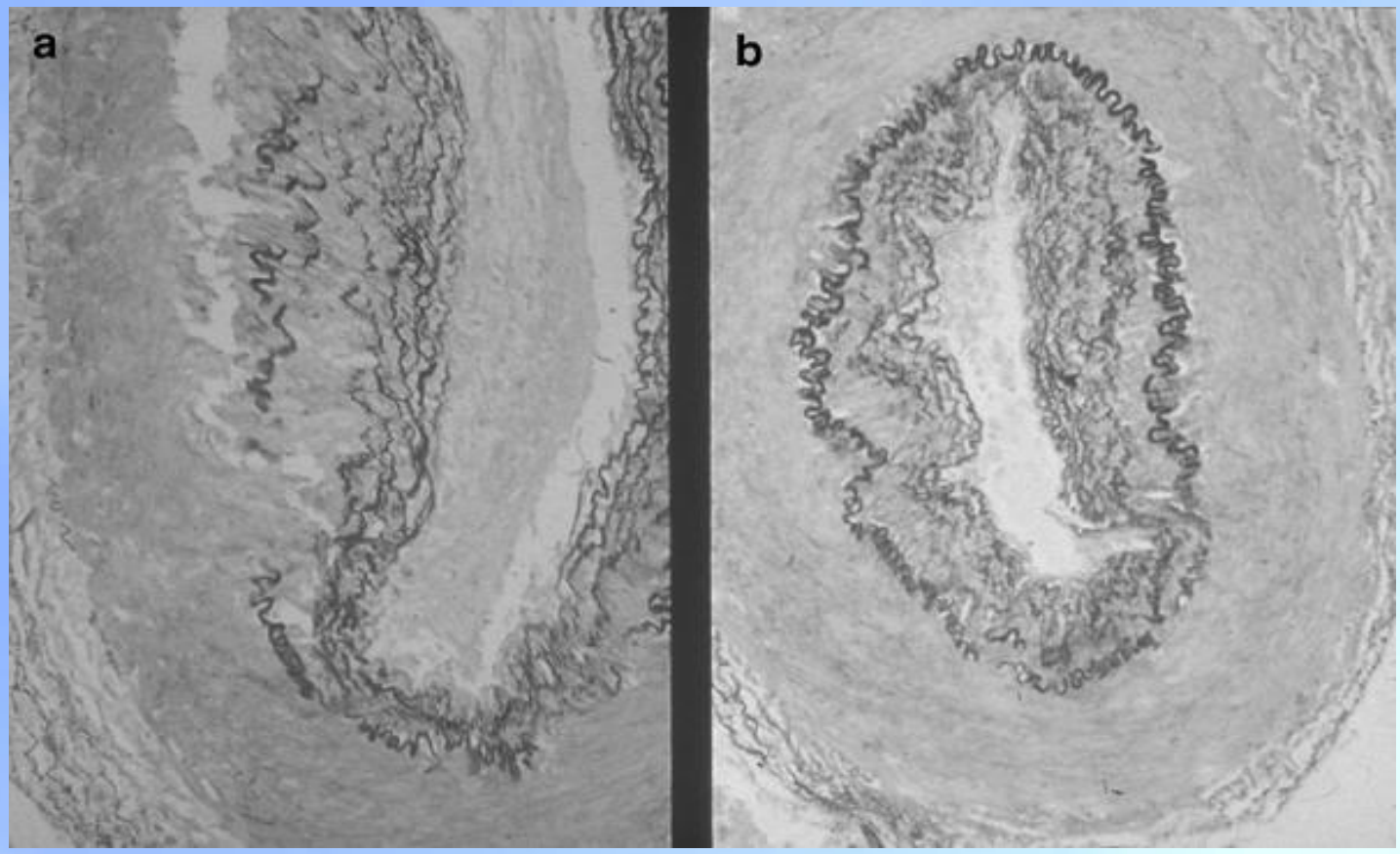

a) Patient's temporal artery showing disruption of the elastic lamina and of the muscle by giant cell arteritis. (b) Control patient temporal artery biopsy showing arteriosclerosis only.

鉴别诊断：

风湿性多肌痛(polymyalgia rheumatica，PMR)

- 以全身疼痛和僵硬伴血沉明显增快为特征的特殊的风湿状态
- 首发在颈部、肩部臀部和骨盆带的近端肌群

鉴别诊断：

PMR分类标准

(1)发病年龄≥50岁；

(2)颈部、肩胛部及骨盆带肌肉僵痛至少有两处，持续1月以上；

(3)晨僵大于l小时；

(4)血沉≥40mm / h(魏氏法)；

(5)抗核抗体及类风湿因子阴性；

(6)无其他骨骼肌肉疾病依据

(7)小剂量糖皮质激素(泼尼松=<20mg / 日)治疗反应好。

符合上述全部7条才能诊断PMR

GCA分类标准：

(1)发病年龄≥50岁

(2) 新近出现的头痛 新近出现的或出现新类型的局限性头痛

(3)颞动脉病变 颞动脉压痛或触痛、搏动减弱，除外颈动脉硬化所致。

(4)血沉增快 魏氏法测定红细胞沉降率≥50mm/h

(5)动脉活检异常 活检标本示血管炎，其特点为单核细胞为主的炎性浸润或肉芽肿性炎症，常有多核巨细胞

符合上述五条标准中的至少三条可诊断

鉴别诊断：

- 大动脉炎
- 韦格纳肉芽肿
- Tolosa-Hunt 综合症

Giant Cell Arteritis

- 概念
- 流行病学、病因学
- 病理学
- 临床表现
- 辅助检查
- 诊断及鉴别诊断
- 治疗
- 典型病例

治疗：

原则：

1. 为防止失明，一旦疑有巨细胞动脉炎，即应给予足量糖皮质激素并联合免疫抑制剂（如环磷酰胺）
2. 依据病情轻重和治疗反应的个体差异，调整药物种类、剂型、剂量和疗程。

治疗：

起始治疗：

- 首选泼尼松1mg/kg/d，多数患者予以泼尼松60mg/d，顿服或分次口服
- 一般在2~4周内头痛等症状可见明显减轻
- 眼部病变改善较慢
- 必要时可使用甲基泼尼松龙冲击治疗

治疗：

起始治疗：

- 免疫抑制剂一般首选环磷酰胺（CYC）
- CYC 800~1000mg，静脉滴注，3~4周一次
- CYC 200mg，静脉注射，隔日一次
- CYC 100~150mg，口服，每日一次
- 疗程和剂量依据病情反应而定

治疗：

起始治疗：

- MTX 7.5~25mg，每周一次，口服或深部肌肉注射或静脉用药
- 硫唑嘌呤100~150mg/d口服
- 使用免疫抑制剂期间应注意定期查血常规、尿常规和肝肾功能，避免不良反应。

治疗：

维持治疗：

- 起始治疗4~6周
- 病情得到基本控制
- 血沉接近正常可

治疗：

维持治疗：

- 泼尼松每周减5~10mg
- 至20mg/日改为每周减1mg
- 减到10mg/日之后减量更慢
- 一般维持量为5~10mg/日

治疗：

维持治疗：

- 免疫抑制剂的减撤亦应依据病情
- 病情稳定后1~2年（或更长时间）可停药观察
- 血沉虽作为病情活动的指标，但有时并不可靠，仍须结合临床综合判断。

Giant Cell Arteritis

- 概念
- 流行病学、病因学
- 病理学
- 临床表现
- 辅助检查
- 诊断及鉴别诊断
- 治疗
- 典型病例

CASE1

Hematoxylin- and eosin-stained superficial temporal artery biopsy specimen, cross section. The hallmark histologic features of GCA shown here include intimal thickening with luminal stenosis, mononuclear inflammatory cell infiltrate with media invasion and necrosis, and giant cell formation in the media.

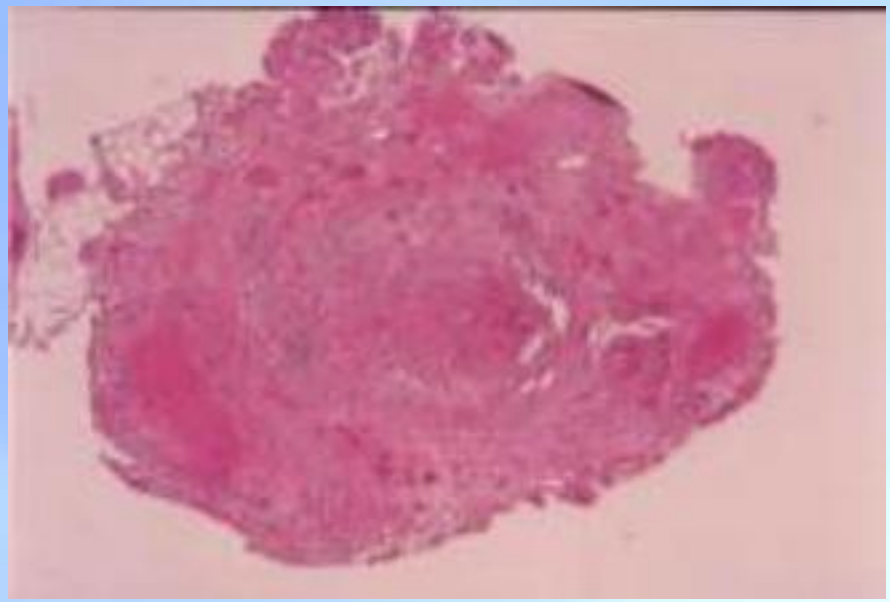

CASE1

Lumbar angiogram showing stenosis and occlusion of femoral artery branches due to vasculitis in the same patient whose temporal artery biopsy specimen in shown in Image 1.

CASE1

Hematoxylin- and eosin-stained femoral artery branch, cross section, taken from a lower limb amputation specimen from the same patient shown in pictures 1 and 2. Mononuclear cell invasion and necrosis in the media of this large artery can be observed. Extensive lower limb vasculitis from GCA resulted in ischemic necrosis of the lower limb, necessitating amputation.

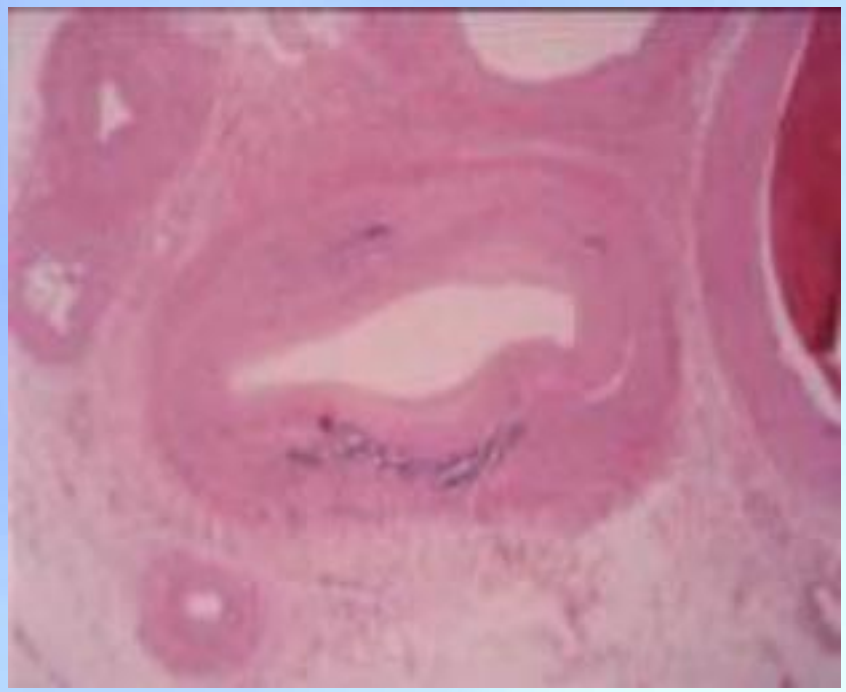

CASE2

- An 85 year old lady
- presented with nausea, vomiting, spiking temperature, constipation, blurry vision, epigastric and central abdominal tenderness.
- C-reactive protein of 475
- Erythrocyte sedimentation rate of 95
- white cell count of 25 with a neutrophil count of 22.

CASE2

- Emergency laparotomy with excision of the gangrenous small bowel was performed under general anaesthesia
- Histological diagnosis is consistent with Giant cell arteritis.
- She was treated postoperatively with steroids

CASE2

Patchy inflammation of all layers of the arterial wall with multinucleate giant cells replacing damaged external lamina.

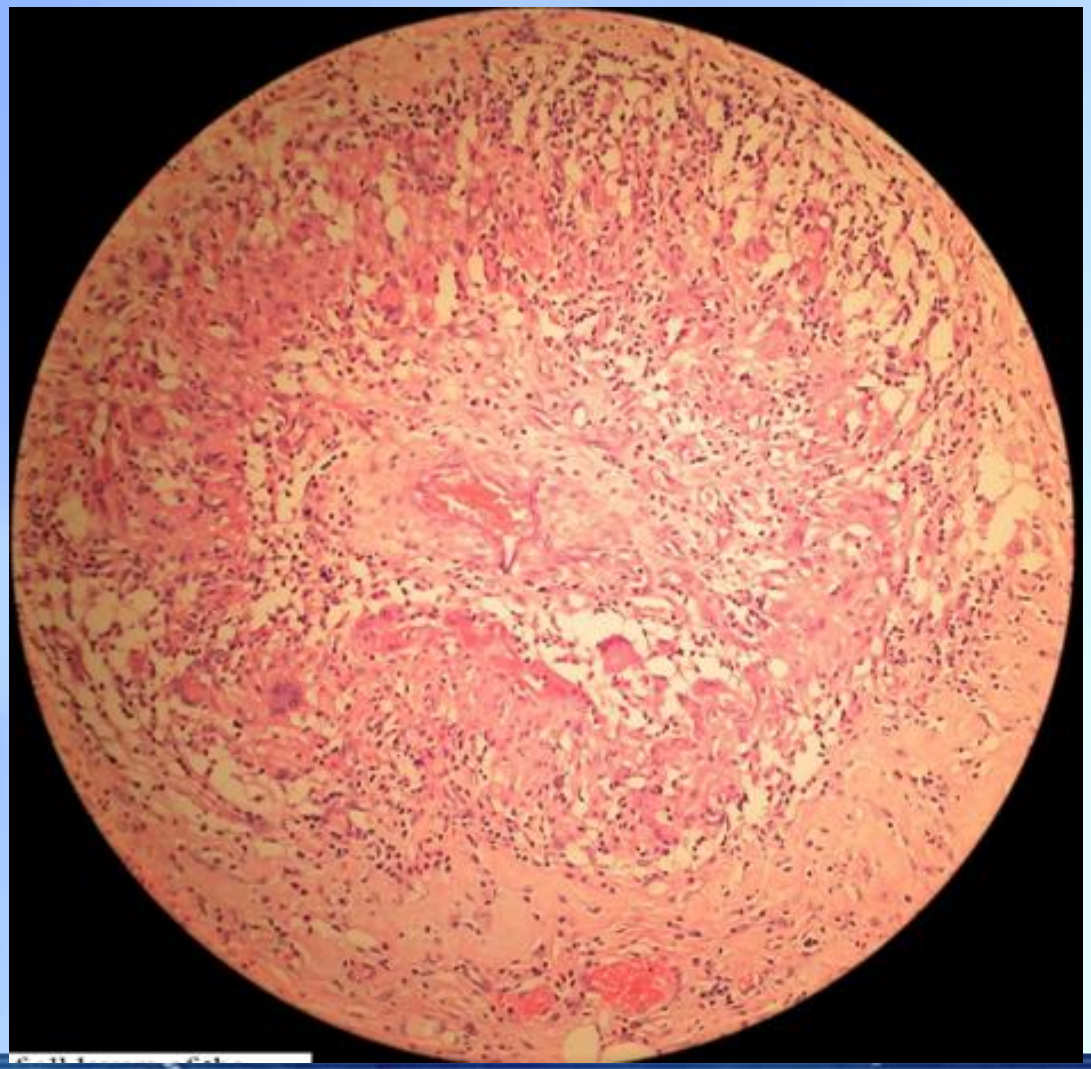

CASE3

A 90 year old woman with painless vision loss

History :

- A 90 year old woman
- presented with sudden, painless loss of vision in her left eye on wakening in the morning 3 days prior.
- She had no associated symptoms of headache, scalp tenderness, jaw claudication, weight loss, or stiffness of the limbs.

CASE3

History :

- Further ophthalmic and systemic inquiry was negative.
- There was no history of hypertension, diabetes, rheumatoid arthritis, or other autoimmune disease.

CASE3

Examination :

- her best-corrected visual acuity was 6/18 in the right eye and perception of light in the left eye.
- There was marked relevant afferent pupillary defect (RAPD) on the left side.
- The extraocular movements were normal.
- Anterior segment of both eyes showed moderate cataracts.

CASE3

Examination :

- The intraocular pressures in both eyes were within the normal range.
- The left optic disc was swollen on funduscopy
- The right disc was normal appearing with a cup to disc ratio of 0.3.
- The superficial temporal arteries were pulsatile and non-tender.

CASE3

Ancillary Testing :

- ESR on initial presentation was 37mm/hr
- Hemoglobin was 13.5
- Platelets were 432
- A diagnosis of anterior ischemic optic neuropathy (AION) was made.

CASE3

Ancillary Testing :

- Although the clinical features were not typical of giant cell arteritis (GCA), in view of the marked visual loss in the left eye this possibility was reconsidered after 48 hours.
- Repeat ESR after 48 hours was 53mm/hr and CRP was 84mg/L.

CASE3

- Marked patchy choroidal ischaemia and leakage at the left optic disc was noted on fundus flourescin angiography.

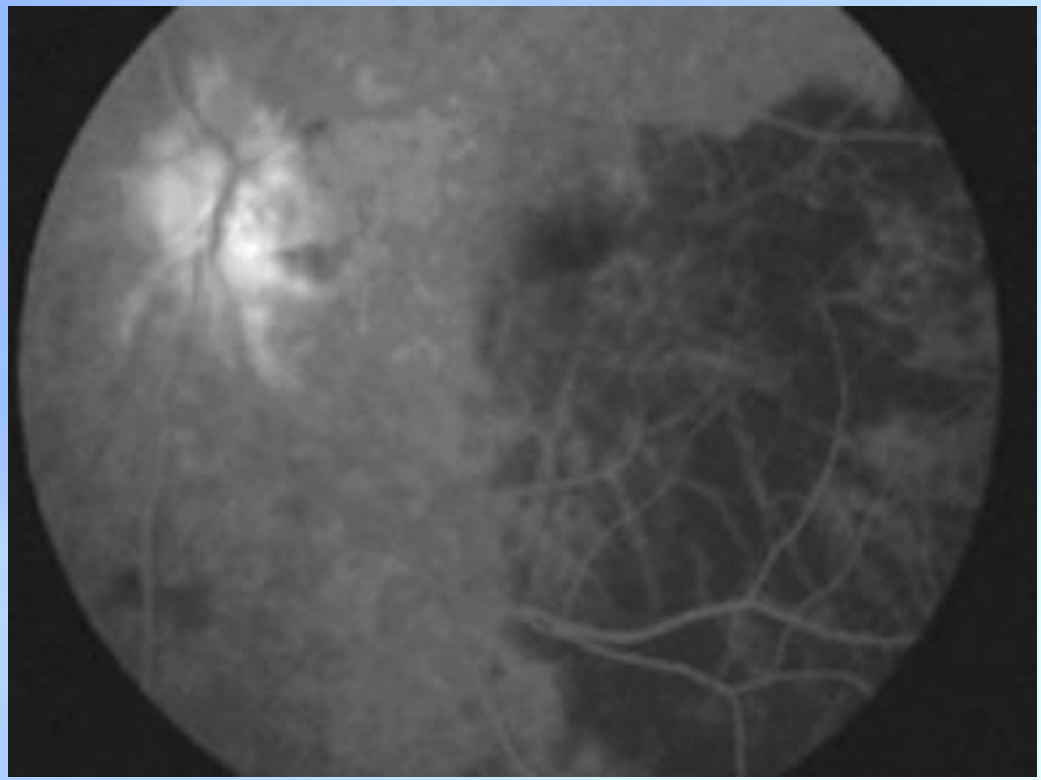

CASE3

Temporal artery biopsy was performed and showed infiltration of the tunica adeventitia with chronic inflammtory infiltrate including giant cells, confirming the diagnosis of giant cell arteritis.

Arrow points to giant cell

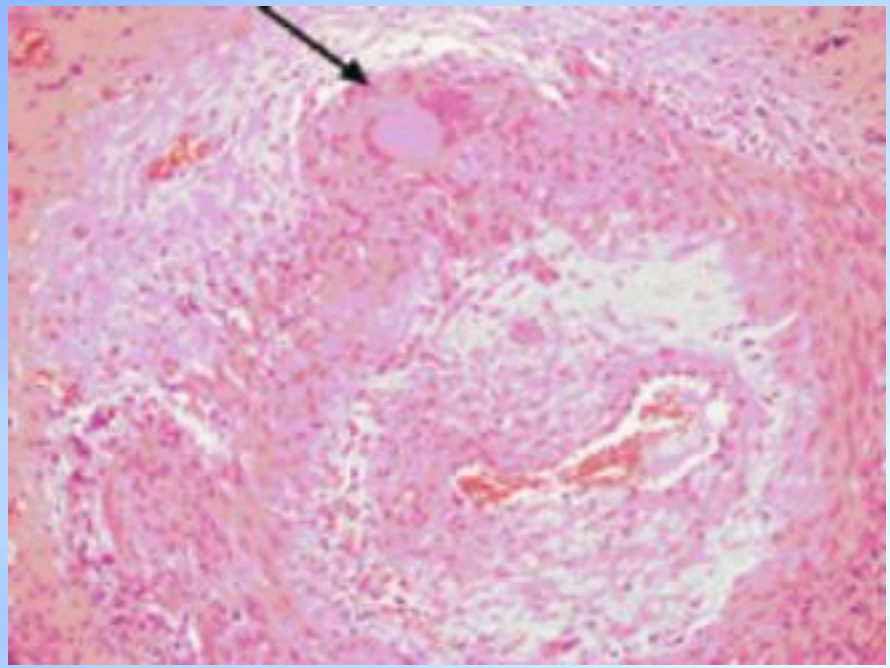

Giant Cell Arteritis

谢谢

南昌大学第二附属医院神经内科

南昌大学第二附属医院
THE HOSPITAL AFFILIATED OF NNACHANG UNIVERSITY